

# Protective effect of the thoracic cage on parenchyma in response to trauma direction in blunt thoracic trauma: an experimental study

Künt toraks travmasında göğüs kafesinin travma yönüne göre parenkim koruyucu etkisi: Deneysel çalışma

Ş. Kerem ÖZEL,<sup>1</sup> H. Banu ÖZEL,<sup>2</sup> Neriman ÇOLAKOĞLU,<sup>2</sup>  
Nevin İLHAN,<sup>3</sup> Nurettin ARSLAN,<sup>4</sup> Enver OZAN<sup>2</sup>

## BACKGROUND

We aimed to investigate the protective potential of the thoracic cage on the parenchyma in response to blunt trauma from different directions in an animal model.

## METHODS

Female Wistar albino rats were divided into control, anterolateral, lateral and posterolateral trauma groups, with six rats in each group. A weight of 500 g was dropped from a height of 40 cm on the left hemithorax to produce an energy of 1.96 joules, using a specially designed platform. Respiratory rates and heart rates were noted before and at 0, 1, and 5 minutes after trauma. Twenty-four hours later, the left lungs were excised for wet lung weight measurement, histological examinations and tissue malondialdehyde determination.

## RESULTS

Severe pulmonary contusion was observed in all trauma groups according to histological parameters. Malondialdehyde was increased in both the lateral and posterolateral groups. Wet lung weight was increased only in the posterolateral trauma group when compared to controls. Histologically, macrophages were increased and mononuclear cell infiltration was significant in the posterolateral trauma group. There were no significant changes in physiological parameters in the groups.

## CONCLUSION

Lung parenchyma seems to be badly affected after trauma to the posterolateral thoracic wall. Different thoracic regions may respond differently to the same traumatic stress, and this may be related to the biomechanical properties of the thoracic cage.

**Key Words:** Blunt trauma; parenchymal injury; thorax.

## AMAÇ

Bu çalışmanın amacı değişik yönlerden gelen künt travmaya karşı göğüs kafesinin parenkim koruyucu potansiyelini deneysel bir hayvan modelinde araştırmaktır.

## GEREÇ VE YÖNTEM

Dişi Wistar albino sıçanlar, herbirinde 6 adet olmak üzere kontrol, anterolateral, lateral ve posterolateral travma grupları olarak ayrıldı. Deney için özel imal edilen bir platformda kinetik enerjisi 1,96 jul olacak şekilde 500 gr'lık bir ağırlık 40 cm'lik bir yükseklikten sol hemitoraks bölgelerine düşürüldü. Travma öncesi ve travmadan 0, 1 ve 5 dakika sonra solunum sayısı ile kalp tepe atımı not edildi. Travmadan 24 saat sonra sol akciğer; yaş akciğer ağırlığı, histoloji ve doku malondialdehid tayini için eksize edildi.

## BULGULAR

Tüm travma gruplarında, histolojik olarak kontrol grubuna göre ciddi akciğer kontüzyonu olduğu gözlemlendi. Malondialdehid hem lateral hem de posterolateral travma grubunda artarken kontrol grubuna göre yaş akciğer ağırlığının sadece posterolateral travma grubunda arttığı saptandı. Histolojik olarak pigmente hücre artışı ve mononükleer hücre infiltrasyonu posterolateral travma grubunda anlamlı bulundu. Fizyolojik parametrelerde anlamlı bir değişiklik saptanmadı.

## SONUÇ

Göğüs kafesinin posterolateral bölgesinden alınan travmalarda akciğer parenkimi daha şiddetli etkilenebilmektedir. Farklı göğüs bölgelerinin aynı künt travma stresine farklı cevaplarının olabileceği ve bu cevapların göğüs kafesinin biyomekanik özelliklerine bağlı olabileceği düşünülmektedir.

**Anahtar Sözcükler:** Künt travma; parenkim hasarı; toraks.

Departments of <sup>1</sup>Pediatric Surgery, <sup>2</sup>Histology and Embryology, <sup>3</sup>Biochemistry, Firat University Faculty of Medicine, Elazığ; <sup>4</sup>Department of Mechanical Engineering, Balıkesir University, Faculty of Engineering, Balıkesir, Turkey.

Firat Üniversitesi Tıp Fakültesi, <sup>1</sup>Çocuk Cerrahisi Anabilim Dalı, <sup>2</sup>Histoloji ve Embriyoloji Anabilim Dalı, <sup>3</sup>Biyokimya Anabilim Dalı, Elazığ; <sup>4</sup>Balıkesir Üniversitesi Mühendislik Fakültesi, Makine Mühendisliği Bölümü, Balıkesir.

Blunt thoracic trauma is a serious cause of morbidity and mortality and is mostly associated with vehicle accidents. Parenchymal injury is the most commonly identified end result and comprises 10-17% of all trauma admissions. Mortality associated with this type of injury is significant and estimated to be 10-25%.<sup>[1,2]</sup>

Masonry arches are the preferred type of architecture especially in historic structures.<sup>[3,4]</sup> The reason for this lies in their ability to equally distribute the force load applied over the convex surface. The shape of these arches determines their capacity to carry force load.<sup>[4]</sup> As a principle, it is easier to collapse an arch from its concave rather than its convex surface.

The thoracic cage has an appearance similar to these masonry arches. It is expected to have similar force distribution due to this biomechanical property, as it has a similar convex surface. No study has been found in the literature regarding the potential of different regions of the thoracic cage to protect the lung in blunt thoracic trauma. Thus, we aimed to investigate the severity of parenchymal injury when the same force load was applied to different points of the thoracic cage in an experimental model.

## MATERIALS AND METHODS

This study was performed in an institutional experimental research center. Permission was obtained from the local ethics committee before the onset of the study. Twenty-four female, Wistar albino rats were used in the study. Rats were not fasted before the experiment and general anesthesia was applied to all animals. General anesthesia was achieved with intramuscular 5 mg/kg ketamine (Ketalar®, Pfizer) and 1 mg/kg



Fig. 1. The trauma platform specially designed for the study.

xylazine hydrochloride (Rompun®, Bayer) injection. Animals were warmed after the experiment to prevent heat loss, and kept under spontaneous respiration. Animals were fed *ad libitum* and allowed to drink water after the experiment.

A special platform unique for this study was designed and produced in the mechanical engineering laboratories of our university (Fig. 1). This platform consisted of a metallic tube fixed to two metal rods to maintain adjustable height determination with the help of a ruler next to this tube. The tube was designed so that different metallic weights suitable for the radius of the tube could be produced, and this tube was kept short to exclude the impact of friction during free fall of the mass. The animals were placed under this tube and blunt trauma was generated with the free fall of the weight over the desired location on the thoracic wall.

The energy of the trauma was calculated using the formulations below:

$$v = 4.429 \cdot \sqrt{h} \dots \text{m/s}$$

$$E = 1/2 \cdot m \cdot v^2 \dots \text{J}$$

h: height that the mass was dropped (meters)

v: impact velocity (meter/seconds)

m: mass (kilograms)

E: absorbed energy by the animal (joules)

A weight of 500 g was dropped from a height of 40 cm to create a trauma energy of 1.96 joules (J) over the left hemithorax of the rats.

The subjects were randomized into four groups as described below:

### Control Group (n=6)

Rats were anesthetized, and their respiratory rates and heart rates were noted. The left lung was totally excised via immediate median sternotomy. Wet lung weight was measured and lung tissue was cut into two equal longitudinal halves for tissue malondialdehyde (MDA) determination and histopathological examination. Cardiac blood sample for blood gas analysis was taken just before the rat was sacrificed with anesthetic overdose.

### Anterolateral Impact Group (n=6)

After anesthesia, the rats were positioned and the impact was generated over the left anterolateral thoracic wall. Respiratory rates and heart rates were noted just before the trauma, just after the trauma, and at 1 and 5 minutes after the trauma. Left lung excision and blood gas sampling were carried out 24 hours after the trauma under general anesthesia with the above-mentioned technique.

### Lateral impact group (n=6)

The study was carried out as in the anterolateral

group, with the exception that trauma was applied to the left lateral thoracic wall. Samples were collected and measurements were done as above.

### Posterolateral impact group (n=6)

The study was carried out with the same method, with the trauma applied to the left posterolateral thoracic wall. Samples were collected and measurements were done as above.

### Blood Gas Sampling

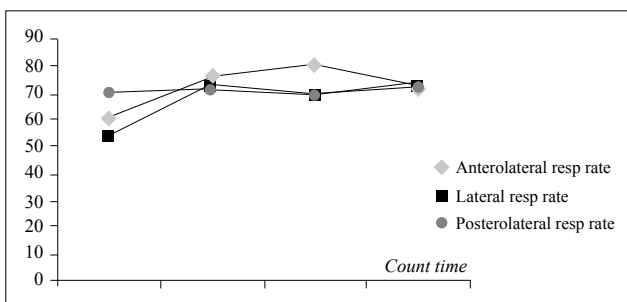
Blood samples were obtained with cardiac puncture, and were taken into heparinized syringes and immediately sent for blood gas sampling. Analysis was done with Rapidlab 348® Blood Gas Analyzer (Siemens Medical Solutions Diagnostics, Deerfield, IL, USA).

### Tissue MDA Determination

After dilution, tissues were homogenized in ice and water at a velocity of 8000 rpm (rates per minute). Homogenates were centrifuged for 60 minutes with Jouan KR221 ultracentrifugation device (Jouan Inc., Winchester, VA, USA), at 30000 g (gravity). These supernatants were used for MDA determination. MDA concentration in lung samples was measured with HPLC (high-performance liquid chromatography) method using Hewlett-Packard model chromatographic series 1100 autosampler (Shimadzu, HPLC VP, Japan) as described by Agarwal et al.<sup>[5]</sup>

### Histopathological Examinations

Lung tissues were fixed in 10% formaldehyde solution after resection. Tissue samples were embedded in paraffin blocks and cut into five micron slices. Samples were stained with hematoxylin-eosin (H&E) and evaluated with light microscopy with Olympus BH2 microscope. In every sample, microscopical fields were examined and scored semiquantitatively in terms of mononuclear cell infiltration, intrabronchiolar epithelial sloughing, macrophage existence, congestion, and interstitial hemorrhage, under 40 magnification. According to this scoring system, changes in all investigated fields were scored as: 0: no change, 1: mild, 2: moderate, and 3: severe.



**Fig. 2.** Consecutive mean respiratory rates of the groups before the impact, just after the impact, and at one and five minutes after the impact.

### Statistical Analysis

For statistical evaluation, a proper computer program was used. Data were given as mean ± standard deviation. Mann-Whitney U test was used for the comparison of biochemical parameters and one-way ANOVA (analysis of variance), post hoc Tukey and LSD (least significant difference) tests for the hemodynamic parameters and histopathological findings. Friedman test was used to evaluate the significance of consecutive measurement of hemodynamic and respiratory parameters. A value of  $p < 0.05$  was considered as statistically significant.

## RESULTS

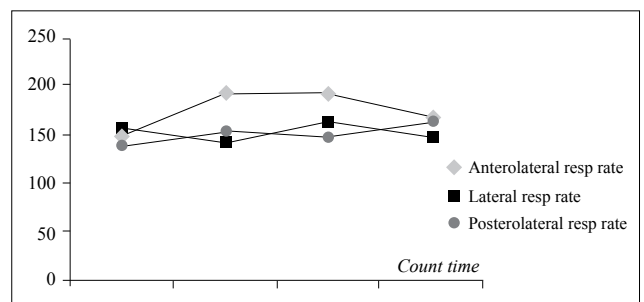
A total of 24 adult Wistar albino rats with a mean weight of  $274 \pm 26.8$  g were included in the study.

### Hemodynamic and Respiratory Parameters

Mean values of hemodynamic and respiratory parameters of the study groups are summarized in Figures 2 and 3. A comparison between the groups of heart rates before the impact, at the time of impact, and 1 and 5 minutes after the impact showed no statistically significant differences except that at the first minute after the anterolateral impact, the mean heart rate was significantly higher than that after posterolateral impact at the same time point ( $190.4 \pm 27.2$  beat/minute vs.  $147.3 \pm 26.6$  beat/minute, respectively,  $p = 0.038$ ). The difference in respiratory rates between the groups at the described count times was not statistically significant ( $p > 0.05$ ). When the consecutive measurements of these parameters in the animals were evaluated, only a significant increase in respiratory rate was observed in the lateral impact group (respiratory rate before impact,  $53.7 \pm 8.6$  per minute, just after impact,  $72 \pm 28.4$  per minute, 1 minute after impact,  $68.7 \pm 11.1$  per minute, and 5 minutes after impact,  $72.3 \pm 24.9$  per minute,  $p = 0.03$ ). No differences were observed in the remainder of the comparisons ( $p > 0.05$ ).

### Wet Lung Weight Measurements

Mean values of wet lung weights of the groups, after the left lungs were excised, were  $402 \pm 28$  milligrams (mg) for the control group,  $407 \pm 37$  mg for the



**Fig. 3.** Consecutive mean heart rates of the groups before the impact, just after the impact, and at one and five minutes after the impact.

**Table 1.** Blood gas analysis and tissue malondialdehyde values of the groups

	Control Group	Anterolateral Group	Lateral Group	Posterolateral Group
pH	7.41±0.03	7.40±0.02	7.42±0.02	7.40±0.02
pO <sub>2</sub> (mmHg)	51±11.2	34±8.7	35.4±11	29.2±15.2*
pCO <sub>2</sub> (mmHg)	43.1±6	54.7±5*	51.8±3.7*	54±3.9*
MDA (nmol/ml)	5.8±4.2	1.8±1	15.9±4.8*	16.4±5.7*

\* p<0.05 when compared to control group, MDA: Malondialdehyde.

anterolateral group, 423±36 mg for the lateral group, and 463±66 mg for the posterolateral group. This ratio was observed to be significantly increased in the posterolateral group when compared to control and anterolateral groups (p=0.03 and p=0.046, respectively).

**Blood Gas Sampling**

pH, pO<sub>2</sub> and pCO<sub>2</sub> values were analyzed and are summarized in Table 1. There was significant hypoxia in the posterolateral group when compared to controls (p=0.021) and significant hypercapnia in all impact groups when compared to controls (p=0.002 for anterolateral group, p=0.02 for lateral group and p=0.004 for posterolateral impact group).

**Tissue Malondialdehyde Determination**

When mean tissue MDA values were evaluated, a significant increase was observed in the lateral and posterolateral groups in comparison with the control group (p=0.003 and p=0.002, respectively) (Table 1). Although the decrease in MDA observed in the anterolateral group was not significant when compared to the control group, this difference was statistically significant when compared to the lateral and posterolateral groups (p=0.000) (Table 1).

**Histopathological Examinations**

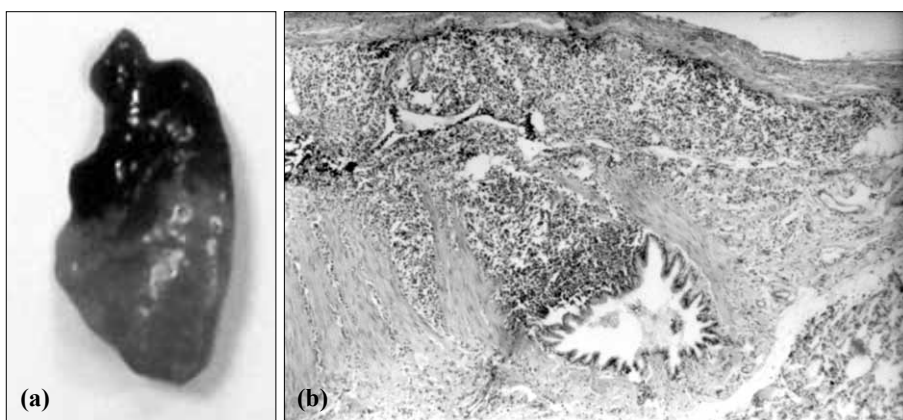
Significant pulmonary contusion was observed in all trauma groups according to histological parameters in comparison with the control group (p<0.05). When mean severity scores of the histopathological parame-

ters were compared, there was significant mononuclear cell infiltration in the posterolateral group in comparison with the anterolateral and lateral groups (posterolateral group: 3.5±0.6, anterolateral group: 2.2±0.5, lateral group: 1.17±0.4, posterolateral vs. anterolateral, p=0.023 and posterolateral vs. lateral, p=0.000) (Fig. 4). When macrophage existence was evaluated, a significant increase was observed in the posterolateral group when compared to the anterolateral group (posterolateral group: 3.2±0.7 and anterolateral group: 2.2±0.5, p=0.046). However, differences in severity scores regarding intrabronchiolar epithelial sloughing, congestion and interstitial hemorrhage were insignificant between the trauma groups.

**DISCUSSION**

Thoracic trauma is a source of high morbidity and mortality. As one of the most commonly identified thoracic injuries, pulmonary contusion denotes a high energy trauma.<sup>[2,6-9]</sup> The presence of pulmonary contusion, together with many other parameters, indicates serious injury to the lung parenchyma, and this is a predictor of outcome in thoracic trauma patients.<sup>[10]</sup> In adults, the most common type of thoracic trauma is rib fracture, whereas in children, pulmonary contusions are the most frequent. The reason for this discrepancy is the pliability of the pediatric thoracic cage.<sup>[1,11]</sup> Thus, it is obvious that the biomechanical properties of the thoracic cage affect the type and extent of the injury secondary to the blunt impact. No previous study has

been found in the literature regarding the protective potential of the thoracic cage against the same blunt impact but from different directions. We aimed to determine this potential in an original experimental model. The original idea of this study came from the observation of masonry arches especially in historic bridges.<sup>[3,4]</sup> This type of construction has been preferred historically by architects for its ability to resist pressure applied to its convex surface as people or convoys pass over the bridges. Different types of



**Fig. 4.** (a) Macroscopic appearance of a contused lung. (b) Mononuclear cell infiltration in the pulmonary interstitium and epithelial sloughing in a bronchiole 24 hours after the posterolateral impact (H-E x 40).

brick masonry arches behave differently to the applied pressures.<sup>[4]</sup> Thus, with its similar shape but different anatomical specifications, like the vertebral column at the back and cartilaginous connections together with sternum in the front, it was decided to examine the thoracic cage from this perspective given the lack of knowledge in the literature.

Various experimental models have been described for blunt thoracic trauma.<sup>[12-16]</sup> Some of these models did not have measurable trauma energy but most studies used a trauma energy between 1.7 and 6.7 J in rats.<sup>[13-17]</sup> We constructed a novel trauma platform for this experiment in collaboration with the department of mechanical engineering in our university. The basic principle of this platform was similar to the experimental model of Raghavendran et al.<sup>[16]</sup> We preferred a trauma energy of 1.96 J as in the study of Türüt et al.<sup>[18]</sup> within the limits described in the literature.<sup>[15,16,18]</sup> The primary aim was to create a quantifiable injury in the lungs and compare its severity. Our model proved itself to form pulmonary injury in terms of physiological, biochemical and histological criteria. This model was also used in two separate studies for the generation of blunt liver trauma in one study and blunt general abdominal trauma in the other.<sup>[17,19]</sup> Thus, it has been validated as a blunt trauma model in different experimental studies.

However, an experimental study on thoracic trauma, including this model, has some inherent difficulties and limitations with respect to the standardization of the force and trauma and evaluation of its consequences. A model can be acceptable in evaluation of a solid organ, but for the chest, which contains multiple vital organs, it is difficult to evaluate the outcome in terms of lung injury alone. This is due to the fact that both pain in a rib fracture, separation or fissure may cause different respiratory rates and heart rates and further, aspiration at the impact time/anesthesia time may cause similar changes in the lung. Moreover, in case of a cardiac trauma (contusion, valve rupture, chorda rupture or papillary muscle rupture), it is difficult to evaluate and discriminate the consequences in such a model.

Parenchymal injury of the lung may result from various mechanisms including (1) direct compression, (2) counter-coup compression, (3) shearing forces, or (4) laceration by fractured ribs.<sup>[20]</sup> Whatever the mechanism, it has been shown that an inflammatory reaction has been activated with the infiltration of macrophages and neutrophils and the coaction of reactive oxygen species (ROS), lipid peroxidation, cytokines, thromboxane, prostacyclines, and apoptosis for the generation of pulmonary injury.<sup>[13,14,18,21,22]</sup>

Knöferl et al.<sup>[23]</sup> used respiratory rate, heart rate, mean arterial pressure and histopathological examinations in order to evaluate the severity of pulmonary injury in their study. Due to technical problems, we were

unable to obtain mean arterial pressure measurements in rats but preferred to add wet lung weight, blood gas analysis and tissue MDA determination for local activity of lipid peroxidation, which were used in other similar studies, in order to predict the severity of the injury.<sup>[18,21]</sup> Wet/dry lung weight ratio is generally the preferred parameter to measure lung water accumulation, but as the technique of this measurement was not suitable for the methodology of the present study, we preferred to measure only the wet lung weight in contradiction to the general information in the literature.<sup>[24]</sup>

When the physiological parameters of the study were evaluated, we observed a significant increase in the heart rate of the rat when the impact was applied to the left anterolateral chest in comparison to the posterolateral impact. This finding was interpreted by the proximity of this region of the chest to the heart and a possible cardiac contusion at the time of the impact. There were no other significant changes in regard to the direction of the impact in the other groups. In terms of respiratory rate, we noted an increase in consecutive respiratory measurements in the lateral impact group. Perhaps the most important weak point of this model is that the animal has to be placed laterally for lateral impact and as the rat is placed on a rigid, flat surface, it is possible that the contralateral lung may also be affected from a left lateral impact due to total compression of the torso. This may explain the increased respiratory rate from a lateral impact rather than the response of the thoracic cage itself, as there was no significant change in the rest of the groups.

Intraparenchymal hemorrhage and edema are important findings of pulmonary contusion.<sup>[18,22]</sup> An increase in lung weight can be expected as a result of hemorrhage and congestion; thus, we measured the wet lung weights of the rats after the study. A significant increase was only observed after posterolateral impact, which may be interpreted as a sign of severe pulmonary injury.

All subjects responded to the trauma with hypercapnia but hypoxemia was prominent only in the posterolateral impact group. Histopathological findings could be seen in all study groups, indicating that pulmonary injury was achieved in all these rats. This might be the reason for the hypercapnia but the injury might be more severe from the posterolateral direction, as hypoxemia was more prominent in this group.

An immunological response is mediated after the generation of injury with the action of activated neutrophils and macrophages in pulmonary contusion. This response results in the increase of ROS and increased lipid peroxidation due to the effects of these radicals. MDA is a good indicator of this activity and used for the prediction of oxidative damage.<sup>[18,21]</sup> We studied the levels of tissue MDA biochemically to

determine local changes in this parameter. MDA was found to be increased only in the lateral and posterolateral impact groups.

Inflammatory cell infiltration, intra-alveolar hemorrhage, alveolar disruption, and congestion are the major histopathological findings after pulmonary contusion.<sup>[16,18,22]</sup> Hoth et al.<sup>[22]</sup> demonstrated significant mononuclear and polymorphonuclear cell infiltration at the 24th hour after pulmonary contusion in rats. Similarly, we observed a significant increase in these histological parameters in all trauma groups. However, mononuclear and macrophage infiltration was more prominent after posterolateral impact. This denotes an increased inflammatory reaction after a blunt trauma from the posterolateral direction.

In conclusion, we observed that a posterolateral impact creates the most harmful effect on the lungs, both physiologically, biochemically and histologically. Anterolateral impact creates the least significant effect, whereas lateral impact creates an effect in between. Costovertebral joints and the thoracic cage are important elements that stabilize the thoracic spine.<sup>[25]</sup> This anatomical interaction may affect the response of the thoracic cage to the trauma as well. Depending on the direction of the trauma, lung parenchyma may be relatively protected after anterolateral impact more than from the other directions due to a more stable configuration of the thoracic cage posteriorly. On the contrary, posterolateral impacts may put the lungs in a more vulnerable situation due to flexibility of anterior elements of the thoracic wall. Although the shape of the thorax is similar to the ancient masonry arches, its anatomical specifications may have a role in the distribution and conduction of trauma energy to the interior organs, which finally affects the extent of the injury.

## REFERENCES

- Wesson DE. Thoracic injuries. In: Grosfeld JL, O'Neill JA, Coran AG, Fonkalsrud EW, editors. Pediatric surgery. Philadelphia: Mosby Elsevier Inc.; 2006. p. 275-95.
- Stitzel JD, Gayzik FS, Hoth JJ, Mercier J, Gage HD, Morton KA, et al. Development of a finite element-based injury metric for pulmonary contusion part I: model development and validation. *Stapp Car Crash J* 2005;49:271-89.
- Toker S, Ünay Aİ. Mathematical modeling and finite element analysis of masonry arch bridges. *GU Journal of Science* 2004;17:129-39.
- Kanit R, Işık NS. Experimental behavior of brick masonry arches and analyses by computer models. [Article in Turkish] *J Fac Eng Arch Gazi Univ* 2007;22:13-20.
- Agarwal R, Chase SD. Rapid, fluorimetric-liquid chromatographic determination of malondialdehyde in biological samples. *J Chromatogr B Analyt Technol Biomed Life Sci* 2002;775:121-6.
- Esme H, Solak O, Yürümez Y, Yavuz Y. The factors affecting the morbidity and mortality in chest trauma. *Ulus Travma Acil Cerrahi Derg* 2006;12:305-10.
- Balci AE, Kazez A, Eren S, Ayan E, Ozalp K, Eren MN. Blunt thoracic trauma in children: review of 137 cases. *Eur J Cardiothorac Surg* 2004;26:387-92.
- Haxhija EQ, Nöres H, Schober P, Höllwarth ME. Lung contusion-lacerations after blunt thoracic trauma in children. *Pediatr Surg Int* 2004;20:412-4.
- Cakan A, Yuncu G, Olgaç G, Alar T, Sevinç S, Ors Kaya S, et al. Thoracic trauma: analysis of 987 cases. *Ulus Travma Derg* 2001;7:236-41.
- Virgós Señor B, Nebra Puertas AC, Sánchez Polo C, Broto Civera A, Suárez Pinilla MA. Predictors of outcome in blunt chest trauma. [Article in Spanish] *Arch Bronconeumol* 2004;40:489-94. [Abstract]
- Özel ŞK, Kazez A. Çocuklarda toraks travmaları. [Article in Turkish] *Klinik Çocuk Forumu* 2003;3:39-44.
- Cohn SM, Zieg PM. Experimental pulmonary contusion: review of the literature and description of a new porcine model. *J Trauma* 1996;41:565-71.
- Davis KA, Fabian TC, Croce MA, Proctor KG. Prostanoids: early mediators in the secondary injury that develops after unilateral pulmonary contusion. *J Trauma* 1999;46:824-32.
- Liener UC, Knöferl MW, Sträter J, Barth TF, Pauser EM, Nüssler AK, et al. Induction of apoptosis following blunt chest trauma. *Shock* 2003;20:511-6.
- Wang ND, Stevens MH, Doty DB, Hammond EH. Blunt chest trauma: an experimental model for heart and lung contusion. *J Trauma* 2003;54:744-8.
- Raghavendran K, Davidson BA, Helinski JD, Marschke CJ, Manderscheid P, Woytash JA, et al. A rat model for isolated bilateral lung contusion from blunt chest trauma. *Anesth Analg* 2005;101:1482-9.
- Cezaoğlu YZ. The effects of copper, zinc and vitamin complex (Cermevit®) administration on liver healing in rats with experimental blunt liver trauma. Specialty thesis. Firat University Faculty of Medicine Department of General Surgery, Elazığ, Turkey, 2008.
- Türüt H, Ciralik H, Kilinc M, Ozbag D, Imrek SS. Effects of early administration of dexamethasone, N-acetylcysteine and aprotinin on inflammatory and oxidant-antioxidant status after lung contusion in rats. *Injury* 2009;40:521-7.
- Kafadar H. Comparison of internal organ injuries in rats with full and empty stomach after blunt abdominal trauma. Specialty thesis. Firat University Faculty of Medicine Department of Forensic Medicine, Elazığ, Turkey, 2008.
- Wagner RB, Crawford WO Jr, Schimpf PP. Classification of parenchymal injuries of the lung. *Radiology* 1988;167:77-82.
- Osuna E, Pérez-Cárceles MD, García-Lorente A, Sánchez-Hanke M, Vieira DN, Carvalho L, et al. Lipid peroxidation in lung tissue after chest trauma and correlation with the duration of the post-trauma survival period. *Int J Legal Med* 1998;111:256-60.
- Hoth JJ, Stitzel JD, Gayzik FS, Brownlee NA, Miller PR, Yoza BK, et al. The pathogenesis of pulmonary contusion: an open chest model in the rat. *J Trauma* 2006;61:32-45.
- Knöferl MW, Liener UC, Seitz DH, Perl M, Brückner UB, Kinzl L, et al. Cardiopulmonary, histological, and inflammatory alterations after lung contusion in a novel mouse model of blunt chest trauma. *Shock* 2003;19:519-25.
- Kitamura Y, Hashimoto S, Mizuta N, Kobayashi A, Kooguchi K, Fujiwara I, et al. Fas/FasL-dependent apoptosis of alveolar cells after lipopolysaccharide-induced lung injury in mice. *Am J Respir Crit Care Med* 2001;163:762-9.
- Oda I, Abumi K, Lü D, Shono Y, Kaneda K. Biomechanical role of the posterior elements, costovertebral joints, and rib cage in the stability of the thoracic spine. *Spine (Phila Pa)* 1976;21:1423-9.