


RANK and RANKL Expression in Salivary Gland Tumors

Ear, Nose & Throat Journal
2020, Vol. 99(7) 475–480
© The Author(s) 2020
Article reuse guidelines:
sagepub.com/journals-permissions
DOI: 10.1177/0145561320930640
journals.sagepub.com/home/ear



Figen Aslan, MD¹, and Ülkü Küçük, MD²

Abstract

Objectives: The pathogenesis and molecular basis of salivary gland tumors (SGT) are not well understood. We investigated the expression of receptor activator of nuclear factor κ B (RANK) and RANK ligand (RANKL) in benign and malignant SGTs and their relationship with clinicopathological features. **Methods:** Fifty malignant and 38 benign SGTs were analyzed in this study. We evaluated the correlation between RANK and RANKL expression and benign and malignant tumors, as well as the correlation between clinicopathological prognostic parameters and RANK and RANKL expression. **Results:** Receptor activator of nuclear factor κ B was positive in 82% (41) malignant SGTs and in 34.2% (13) benign SGTs. Receptor activator of nuclear factor κ B ligand was expressed in 28% (14) malignant and 5.3% (2) benign tumors. Receptor activator of nuclear factor κ B and RANKL expression were significantly different between benign and malignant SGTs ($P < .001$, $P = .006$, respectively). However, a relationship was not found between positive expression of RANK or RANKL and clinicopathological features. **Conclusions:** In our study, RANK and RANKL expression was found to be higher in malignant SGTs compared to benign SGTs and RANK was more sensitive than RANKL. In addition, RANK and RANKL expression was higher in some malignant histological subtypes. Based on these results, we think that RANK and RANKL expression in SGTs and its potential as a target for treatment should continue to be investigated.

Keywords

expression, RANK, RANKL, salivary gland, tumor

Introduction

Salivary gland carcinomas are rare tumors that make up about 5% of head and neck tumors. These tumors are biologically heterogeneous and have different clinical behaviors. As such, the pathogenesis and molecular basis of these tumors are not well understood due to their complexity.^{1,2}

The receptor activator of nuclear factor κ B ligand (RANKL) is a tumor necrosis factor (TNF) superfamily protein expressed in the surface of osteoblasts and bone marrow stromal cells and is present in carcinomas of various types. It plays a key role in the production, function, and survival of osteoclasts by binding to its own receptor, receptor activator of nuclear factor κ B (RANK), which is expressed on the surface of myeloid osteoclast precursors.³⁻⁵ An increase in RANKL usually stimulates osteoclastogenesis in bone metastases.⁶ In addition, RANK and RANKL are found in several other malignancies including prostate carcinomas,⁶⁻⁸ breast carcinomas,⁹ renal cell carcinomas,¹⁰ lung carcinomas,¹¹ gastric cancer,¹² and endometrial cancer.¹³ There are studies that have effects on the aggressive behavior of the tumor.^{6,9-14} Several studies demonstrate the effect of RANK and RANKL on salivary gland tumors (SGTs),

but the prognostic effect has not yet been elucidated.^{15,16} In order to shed light on its prognostic effects, we investigated the immunohistochemical expression of RANK and RANKL in malignant and benign SGTs as well as its relationship to clinicopathological features.

Patients and Methods

Patients and Tissue Samples

One tumor per patient was taken from a total of 88 patients, yielding 50 malignant and 38 benign SGTs, which were

¹ Department of Pathology, Balıkesir University School of Medicine, Balıkesir, Turkey

² Department of Pathology, Health Sciences University Tepecik Training and Research Hospital, İzmir, Turkey

Received: February 03, 2020; revised: April 24, 2020; accepted: April 28, 2020

Corresponding Author:

Figen Aslan, MD, Department of Pathology, Balıkesir University School of Medicine, Balıkesir, Turkey.

Email: fgenaslan@gmail.com



diagnosed at 2 centers between 2013 and 2018. Age, gender, location, diameter, histological subtype, and grade (low or high) of SGTs were taken from medical charts and pathology records.

Of the 88 SGTs included in the study, 38 (43.2%) were benign and 50 (56.8%) were malignant. Fifteen (39.5%) patients with benign SGTs were female and 23 (60.5%) of them were male, while 21 (42%) female and 29 (58%) male patients had malignant SGTs. The median age of benign SGT cases was 53.8 years (min: 20, max: 86), and 27 (71.1%) of these cases were age 65 or older. The median age of the patients with malignant SGTs was 58.1 years (min: 17, max: 95), and 33 (66%) of them were 65 years of age or older. All benign SGTs were located in the major salivary gland (36 parotid, 2 submandibular glands), whereas only 15 (30%) of malignant tumors originated from the minor, and 35 (70%) of them originated from the major salivary glands (31 from the parotid gland and 4 from the submandibular gland). The median diameters of the benign and malignant tumors were 2.7 cm (min: 1 cm, max: 5.5 cm) and 3.5 cm (min: 0.7 cm, max: 10 cm), respectively.

Tumor type varied with 22 (57.9%) benign tumors being pleomorphic adenomas and 16 (42.1%) Warthin tumors. Sixteen (32.7%) patients with malignant SGTs had mucoepidermoid carcinomas (MECs), 13 (26.5%) patients had adenoid cystic carcinomas, 6 (12.2%) patients had carcinoma ex pleomorphic adenomas (CaExpAs), 5 (10.2%) had acinic cell carcinomas, 3 (6.1%) had basal cell carcinomas, and 2 (4.1%) had squamous cell carcinomas. A salivary duct carcinoma, a polymorphous adenocarcinoma, an epithelial-myoepithelial carcinoma, and a clear cell carcinoma were each found in only one patient.

Immunohistochemistry

The paraffin blocks of 88 SGTs, each with a thickness of 4 microns, were placed on positively charged slides and melted with the Ventana Benchmark XT device. Cell Conditioner 1 solution was applied to the slides to reveal the antigen. Subsequently, hydrogen peroxide was applied for 7 minutes to mask endogenous peroxidase. Primary antibodies for RANK (Santa Cruz sc-52951; 1/50 dilution), RANKL (Santa Cruz sc-52950; 1/100 dilution), human epidermal growth factor receptor 2 (HER2; Cell Marque/RabMab; 1/50 dilution), and Ki-67 (Dako Flex; 1/100 dilution) were dropped manually for 30 minutes for incubation. Then, the Ultra View Universal DAB Detection kit secondary antibody was applied for 10 minutes. Contrast staining using this device was performed with hematoxylin, applied for 8 minutes, followed by background staining with Bluing Reagent solution. Dehydration of the slides taken from the device was performed with alcohol, and transparency was rendered with xylene. Finally, slides were covered with coverslips.

Interpretation of Immunohistochemistry

Regardless of the extent or intensity, RANK and RANKL staining were considered positive when the cytoplasm showed a

positive reaction. The staining intensities were graded as 1+ (weakly positive/light yellow), 2+ (moderately positive/yellow-brown), and 3+ (strongly positive/brown). Immunohistochemical evaluation for HER2 was performed according to the recommendations of the American Society of Clinical Pathology related to the evaluation of HER2 in breast cancer.¹⁷ Human epidermal growth factor receptor 2 immunostaining was considered to be positive when at least 30% of the tumor cells were stained. Brown nuclear staining for Ki-67 was considered positive. Immunoreactivity was expressed as a percentage of positively stained tumor cells.

Statistical Analysis

Statistical analysis was performed using the Statistical Package of Social Sciences version 24 (IBM Corp). In addition to the correlation between RANK or RANKL and benign or malignant tumors, the correlation between clinicopathological prognostic parameters and RANK and RANKL expression was evaluated using the χ^2 test and Fisher exact test. Values of P less than .05 were considered statistically significant.

Results

Immunohistochemically, RANK was positive in 41 (82%) cases and negative in 9 (18%) cases out of 50 cases with malignant SGTs. In benign SGTs, RANK was positive in 13 (34.2%) cases and negative in 25 (65.8%) cases (Figure 1). When malignant SGTs were graded by staining intensity, 22 scored 1+, 16 scored 2+, and 3 scored 3+. In 13 benign SGTs, 11 cases scored 1+, and 13 cases scored 2+.

In malignant tumors, RANKL was positive in 14 (28%) and negative in 36 (72%). In benign tumors, it was negative in 2 (5.3%) and positive in 36 (94.7%; Figure 2). Among 14 malignant SGTs with positive staining, 13 tumors had staining intensities of 1+, and 1 tumor had an intensity of 2+. In the 2 benign tumors with positive staining, the staining intensity score was 1+ for both. The results of RANK and RANKL expression according to histological subtypes of malignant SGTs are shown in Table 1.

The difference between the benign and malignant groups in terms of expression of RANK or RANKL was tested by χ^2 analysis. A significant difference was found between benign and malignant SGTs in terms of both RANK and RANKL expression ($P < .001$, $P = .006$, respectively; Figure 3).

Human epidermal growth factor receptor 2 and Ki-67 immunohistochemical markers were also applied to malignant SGTs. Human epidermal growth factor receptor 2 was positive in 14 (28%) malignant tumors and negative in 36 (72%). Ki-67 expression was $\leq 5\%$ in 21 (42%) and $> 5\%$ in 29 (58%) tumors.

The relationship between RANK and RANKL expression with age, sex, tumor grade, tumor diameter, HER2 expression, and Ki-67 proliferative index was tested using χ^2 analysis. No relationship was found between expression of RANK or RANKL and sex, age, tumor grade, or tumor diameter (Table 2). Similarly, there was no correlation between

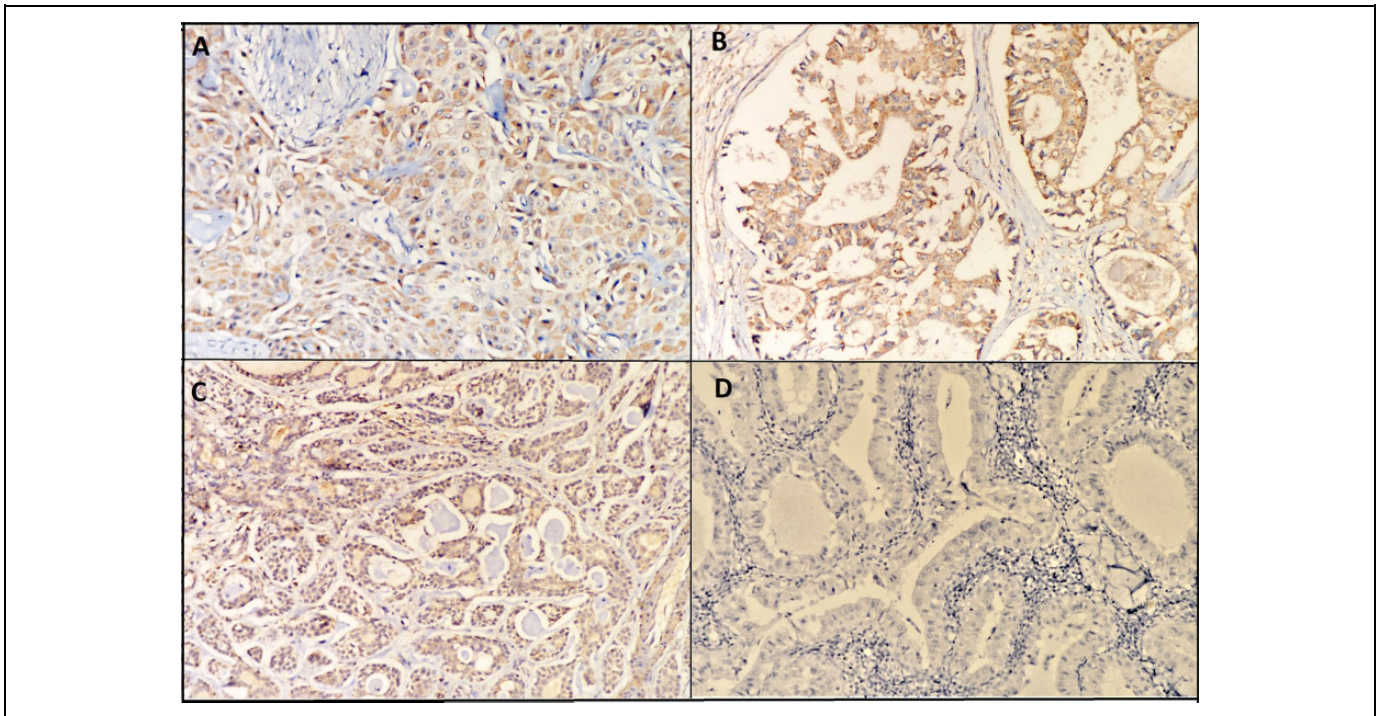


Figure 1. Immunohistochemical RANK (A-D) expression in SGTs (immunohistochemistry, $\times 200$). Positive staining of RANK in oncocytic variant of mucoepidermoid carcinoma (A), positive staining of RANK in mucoepidermoid carcinoma (B), positive staining of RANK in adenoid cystic carcinoma (C), negative staining of RANK in benign tumor (Warthin tumor) (D).

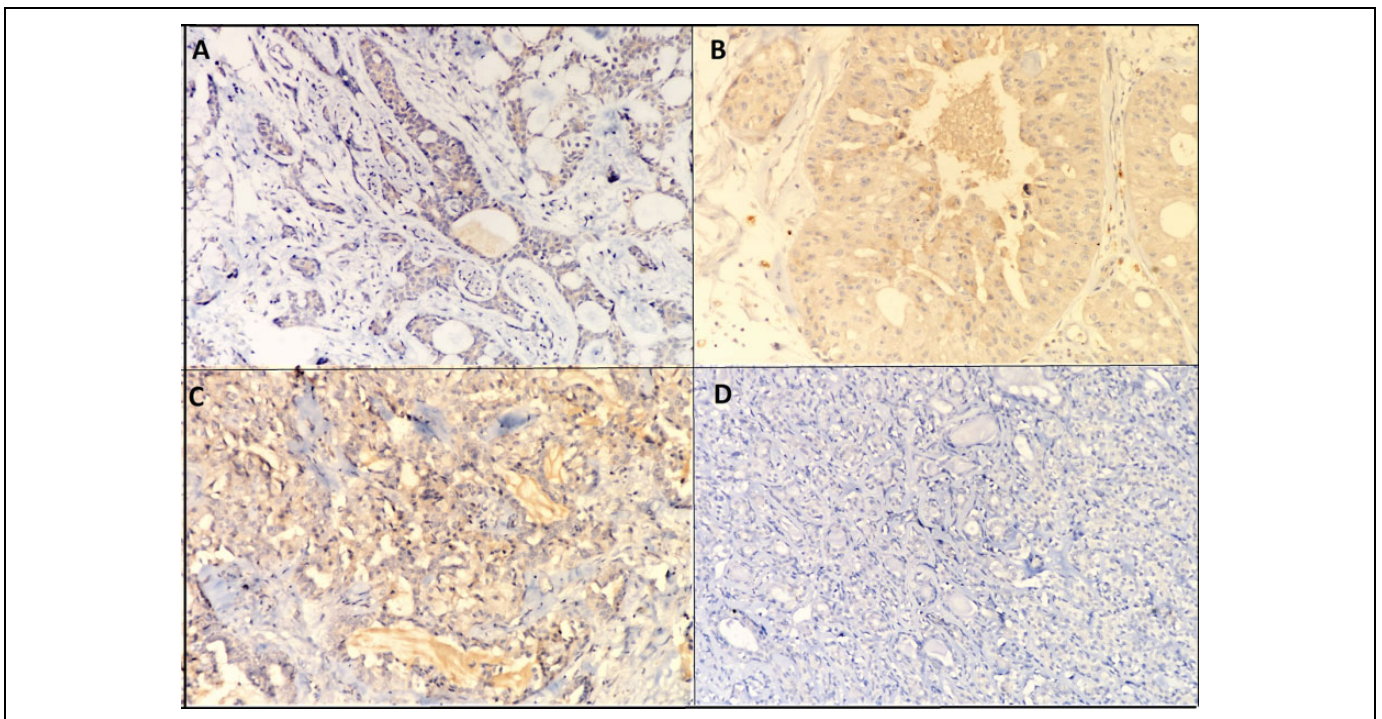


Figure 2. Immunohistochemical RANKL (A-D) expression in salivary gland tumors (immunohistochemistry, $\times 200$). Positive staining of RANKL in adenoid cystic carcinoma (A), positive staining of RANKL in carcinoma ex pleomorphic adenoma (B), positive staining of RANKL in mucoepidermoid carcinoma (C), negative staining of RANKL in benign tumor (pleomorphic adenoma) (D). RANKL indicates receptor activator of nuclear factor κ B ligand.

Table 1. Receptor Activator of Nuclear Factor κ B (RANK) and RANKL Expression According to Histological Subtype of Malignant Tumors.

| Tumor histologic subtype | RANK, n (%), positive/negative | RANKL, n (%), positive/negative |
|--|--------------------------------|---------------------------------|
| Adenoid cystic carcinoma (n = 13) | 11 (84.6)/2 (15.4) | 2 (15.4)/11 (84.6) |
| Mucoepidermoid carcinoma (n = 16) | 16 (100)/0 | 6 (37.5)/10 (62.5) |
| Carcinoma ex pleomorphic adenoma (n = 6) | 6 (100)/0 | 2 (33.3)/4 (66.7) |
| Acinic cell carcinoma (n = 5) | 3 (60)/2 (40) | 1 (20)/4 (80) |
| Basal cell adenocarcinoma (n = 3) | 3 (100)/0 | 0/3 (100) |
| Squamous cell carcinoma (n = 2) | 0/2 (100) | 0/2 (100) |
| Clear cell carcinoma (n = 1) | 0/1 (100) | 0/1 (100) |
| Epithelial-myoepithelial carcinoma (n = 1) | 0/1 (100) | 0/1 (100) |
| Polymorphous adenocarcinoma (n = 1) | 0/1 (100) | 1 (100)/0 |
| Ductal carcinoma (n = 1) | 1 (100)/0 | 1 (100)/0 |
| Adenocarcinoma, NOS (n = 1) | 1 (100)/0 | 1 (100)/0 |

Abbreviations: NOS, not otherwise specified, RANK, receptor activator of nuclear factor κ B, RANKL, receptor activator of nuclear factor κ B ligand.

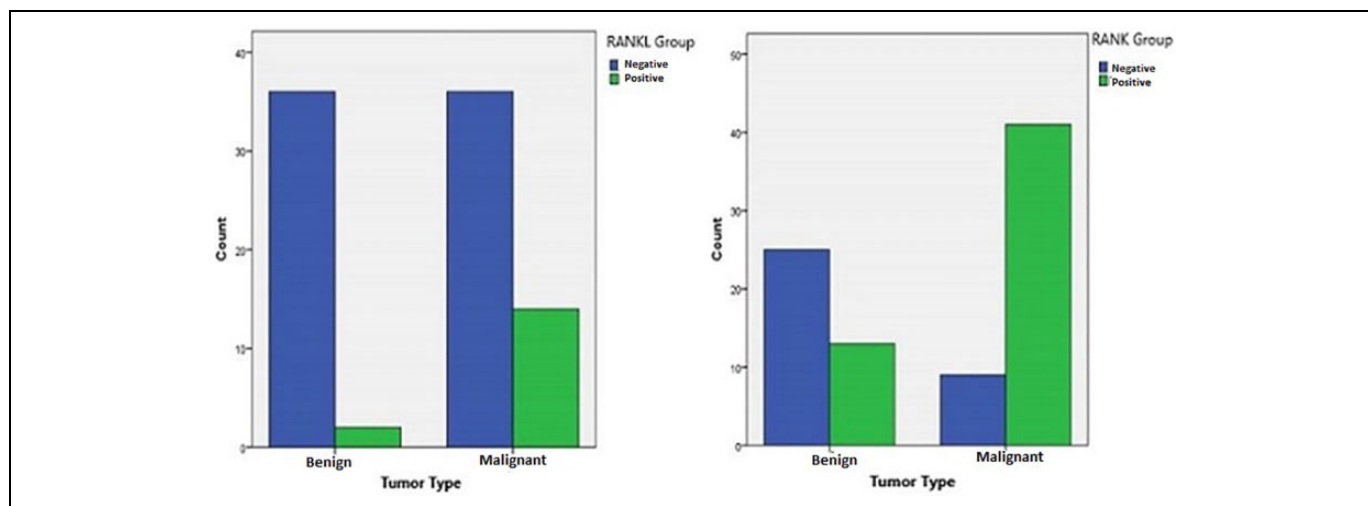


Figure 3. Comparison of benign and malignant groups in terms of expression of RANK and RANKL. RANK indicates, receptor activator of nuclear factor κ B; RANKL, receptor activator of nuclear factor κ B ligand.

expression of RANK or RANKL and HER2 status ($P = 1.00$, $P = .496$, respectively), or Ki-67 proliferative index ($P = .56$, $P = .93$, respectively; Table 2).

Discussion

Understanding the tumorigenesis of aggressive neoplasms in salivary glands is essential to improving the clinical management of these rare tumors, and identifying new prognostic markers is key to this understanding.^{1,2} As a member of the TNF super family, RANKL plays an important role in the formation, function, survival, and bone resorption of osteoclasts, and is often responsible for osteoclastogenesis in bone metastases of malignant tumors.¹⁴ While RANKL inhibitors have successfully treated bone-related pathologies such as osteoporosis, bone metastases, and giant cell tumors of the bone, a recent study has investigated the usability of the RANKL inhibitor in breast tumors.^{18,19} The mouse breast tumor virus-Polyoma Medium T, which mimics the RANK and

RANKL expression patterns seen in human breast adenocarcinomas, successfully inhibited RANK signaling. As a result, the number of cancer stem cells (CSC) and recurrence and metastasis rates decreased, and tumor cell differentiation was induced in invasive breast tumors.¹⁹ The same study also demonstrated that RANKL inhibitors can be used as differentiation therapy in CSC, suggesting a role for such inhibitors for the treatment of SGTs.¹⁹

Mammary glands and salivary glands share many histological and physiological similarities; there are histopathological similarities between breast tumors and SGTs, as well. Considering these similarities, there may also be a relationship between SGTs and RANK and RANKL. However, there is currently a limited number of studies investigating this relationship.^{15,16} In a study by Szwarc et al, the RANKL/RANK signal axis led to an aggressive SGT phenotype at both the histological and molecular level. They also showed that the development of malignant SGTs was markedly reduced by the early blockade of RANKL/RANK signaling.¹⁶

Table 2. Relationship of RANK and RANKL Expression With Sex, Age, Tumor Grade, Size, HER2, and Ki-67 Expression.

| | RANK (+) n (%) | P value | RANKL (+) n (%) | P value |
|--------------------|----------------|---------|-----------------|---------|
| Gender | | | | |
| Female (n = 21) | 18 (85.7) | .716 | 4 (19) | .23 |
| Male (n = 29) | 23 (79.3) | | 10 (34.5) | |
| Age | | | | |
| ≤65 (n = 33) | 27 (81.8) | 1.00 | 9 (27.3) | 1.00 |
| >65 (n = 17) | 14 (82.4) | | 5 (29.4) | |
| Tumor grade | | | | |
| Low (n = 37) | 29 (78.4) | .414 | 9 (24.3) | .474 |
| High (n = 13) | 12 (92.3) | | 5 (38.5) | |
| Tumor size | | | | |
| ≤4 (n = 37) | 31 (83.8) | .679 | 11 (29.7) | .734 |
| >4 (n = 13) | 10 (76.9) | | 3 (23.1) | |
| HER2 | | | | |
| HER2 (+) (n = 14) | 12 (85.7) | 1.00 | 5 (35.7) | .496 |
| HER2 (-) (n = 36) | 29 (80.6) | | 9 (25.0) | |
| Ki-67-Index | | | | |
| ≤5% (n = 21) | 19 (90.47) | .56 | 6 (28.57) | .93 |
| >5% (n = 29) | 22 (75.86) | | 8 (27.58) | |

Abbreviations: HER2, human epidermal growth factor receptor 2; RANK, receptor activator of nuclear factor κ B; RANKL, receptor activator of nuclear factor κ B ligand.

Furthermore, although the overexpression of RANKL targeted both the salivary and mammary glands of mice, palpable tumors were observed only in the salivary glands, demonstrating that salivary gland epithelium is more sensitive to RANKL/RANK signal than mammary gland epithelium.¹⁶

A study of SGTs by Franchi et al investigated protein expression of RANK and RANKL in malignant and benign tumors. They found that both RANK and RANKL had higher expression levels in malignant tumors than in benign tumors, showing that high RANK and RANKL expression indicates the malignant phenotype of the tumor. Our study confirmed these results: expression of RANK and RANKL was significantly higher in malignant tumors than in benign tumors. Franchi et al also found that RANK expression was a more potent marker than RANKL in detecting phenotypes of malignant tumors.¹⁵ Again, our study confirmed that RANK expression was significantly higher in malignant tumors than RANKL expression (82% and 28%, respectively).

When the histological subtypes of SGTs were taken into consideration, Franchi et al reported that RANK expression was observed in the majority of cases with MECs and CaExPAs, but only seen in a small number of cases with adenoid cystic carcinomas. Similarly, in our study, RANK expression was observed in all MEC and CaExPA cases. In contrast to this study, RANK expression was present in the majority of adenoid cystic carcinoma (ACC) cases in our study (n = 13, 84.6%). These results may direct researchers to studies that will include larger samples to guide targeted therapies in particular.

In the study by Franchi et al, no correlation was found between RANK and RANKL expression and tumor prognostic parameters such as histologic grade, stage, local recurrence, facial nerve involvement, nodal and distal metastases, and

survival.¹⁵ Similarly, in our study, no relationship was found between expression of RANK or RANKL and sex, age, tumor grade, or tumor diameter.

Human epidermal growth factor receptor 2 is a member of the human epidermal growth factor receptor family and is associated with a poor prognosis in breast carcinomas.^{20,21} Overexpression of HER2 is also common in salivary gland cancers and is generally associated with a poor prognosis and aggressive tumor behavior.^{22,23} In our study, HER2 was found to be positive in 28% of the patients with malignant SGTs, but there was no correlation between HER2 expression and RANK and RANKL expression.

Ki-67 is one of the most sensitive determinants of cell proliferation potential. Its expression is widely used to determine prognosis in many tumors including breast tumor, suggesting its potential as a marker for malignancy in SGTs.^{1,24} Similar to HER2 and Ki-67, RANK and RANKL are poor prognostic markers for many malignant tumors. However, we did not detect a significant relationship between RANK and RANKL and the proliferative marker Ki-67 as in HER2 expression, a poor prognostic indicator in salivary gland cancer. The reason for this result may be that each marker affects prognosis through different mechanisms.

In conclusion, we found RANK and RANKL expression to be higher in malignant SGTs than in benign SGTs, and RANK in particular was found to be more sensitive than RANKL. In addition, RANK and RANKL expression was observed to be higher in some malignant histological subtypes. Based on these results, we believe that the studies on RANK and RANKL expression in SGT need to be investigated in larger sample sizes, especially with the current emphasis on targeted therapies.


Declaration of Conflicting Interests

The author(s) declared no potential conflicts of interest with respect to the research, authorship, and/or publication of this article.

Funding

The author(s) disclosed receipt of the following financial support for the research, authorship, and/or publication of this article: This study was funded by Balikesir University Coordinator of Scientific Research Projects.

ORCID iD

Figen Aslan  <https://orcid.org/0000-0002-4817-1904>

References

- Shigeishi H, Mitani Y, Ono S, et al. Increased expression of CENP-H gene in human salivary gland carcinomas. *Oral Sci Int.* 2008;5(1):43-51.
- Fonseca FP, Bingle L, Santos Silva AR, et al. Immunoeexpression of *hoxb7* and *hoxb9* in salivary gland tumours. *J Oral Pathol Med.* 2016;45(9):672-681.
- Dougall WC, Glaccum M, Charrier K, et al. RANK is essential for osteoclast and lymph node development. *Genes Dev.* 1999;13(18): 2412-2424.
- Yasuda H, Shima N, Nakagawa N, et al. Osteoclast differentiation factor is a ligand for osteoprotegerin/osteoclastogenesis-inhibitory factor and is identical to TRANCE/RANKL. *Proc Natl Acad Sci.* 1998;95(7):3597-3602.
- Hsu H, Lacey DL, Dunstan CR, et al. Tumor necrosis factor receptor family member RANK mediates osteoclast differentiation and activation induced by osteoprotegerin ligand. *Proc Natl Acad Sci.* 1999;96(7):3540-3545.
- Armstrong AP, Miller RE, Jones JC, Zhang J, Keller ET, Dougall WC. RANKL acts directly on RANK-expressing prostate tumor cells and mediates migration and expression of tumor metastasis genes. *Prostate.* 2008;68(1):92-104.
- Odero-Marah VA, Wang R, Chu G, et al. Receptor activator of NF- κ B Ligand (RANKL) expression is associated with epithelial to mesenchymal transition in human prostate cancer cells. *Cell Res.* 2008;18(8):858-870.
- Chen G, Sircar K, Aprikian A, Potti A, Goltzman D, Rabbani SA. Expression of RANKL/RANK/OPG in primary and metastatic human prostate cancer as markers of disease stage and functional regulation. *Cancer.* 2006;107(2):289-298.
- Pfizner BM, Branstetter D, Loibl S, et al. RANK expression as a prognostic and predictive marker in breast cancer. *Breast Cancer Res Treat.* 2014;145(2):307-315.
- Mikami S, Katsube KI, Oya M, et al. Increased RANKL expression is related to tumour migration and metastasis of renal cell carcinomas. *J Pathol.* 2009;218(4):530-539.
- Scagliotti GV, Hirsh V, Siena S, et al. Overall survival improvement in patients with lung cancer and bone metastases treated with denosumab versus zoledronic acid: subgroup analysis from a randomized phase 3 study. *J Thorac Oncol.* 2012;7(12): 1823-1829.
- Zhang X, Song Y, Song N, et al. Rankl expression predicts poor prognosis in gastric cancer patients: results from a retrospective and single-center analysis. *Br J M Biol Res.* 2018;51(3):e6265.
- Wang J, Liu Y, Wang L, et al. Clinical prognostic significance and pro-metastatic activity of RANK/RANKL via the AKT pathway in endometrial cancer. *Oncotarget.* 2016;7(5):5564-5575.
- Suárez EG, Moreno AS. RANK as a therapeutic target in cancer. *FEBS J.* 2016;283(11):2018-2033.
- Franchi A, Taverna C, Simoni A, et al. RANK and RANK ligand expression in parotid gland carcinomas. *Appl Immunohistochem Mol Morphol.* 2018;26(7):478-482.
- Szwarc MM, Kommagani R, Jacob AP, Dougall WC, Ittmann MM, Lydon JP. Aberrant activation of the RANK signaling receptor induces murine salivary gland tumors. *PLoS One.* 2015;10(6): e0128467.
- Wolff AC, Hammond MEH, Hicks DG, et al. Recommendations for human epidermal growth factor receptor 2 testing in breast cancer: American Society of Clinical Oncology/College of American Pathologists Clinical Practice Guideline update. *Arch Pathol Lab Med.* 2013;142(11):1364-1382.
- Lacey DL, Boyle WJ, Simonet WS, et al. Bench to bedside: elucidation of the OPG-RANK-RANKL pathway and the development of denosumab. *Nat Rev Drug Discov.* 2012;11(5):401.
- Yoldi G, Pellegrini P, Trinidad EM, et al. RANK signaling blockade reduces breast cancer recurrence by inducing tumor cell differentiation. *Cancer Res.* 2016;76(19):5857-5869.
- Alotaibi AM, Alqarni MA, Alnobi A, Tarakji B. Human epidermal growth factor receptor 2 (HER2/neu) in salivary gland carcinomas: a review of literature. *J Clin Diagnostic Res.* 2015;9(2): ZE04.
- Gibo T, Sekiguchi N, Gomi D, et al. Targeted therapy with trastuzumab for epidermal growth factor receptor 2 (HER2) positive advanced salivary duct carcinoma: a case report. *Mol Clin Oncol* 2019;11(2):111-115.
- Press MF, Pike MC, Hung G, et al. Amplification and overexpression of HER-2/neu in carcinomas of the salivary gland: correlation with poor prognosis. *Cancer Res.* 1994;54(21):5675-5682.
- Giannoni C, Naggari AK, Ordonez NG, et al. c-erbB-2/neu oncogene and Ki-67 analysis in the assessment of palatal salivary gland neoplasms. *Otolaryngol Head Neck Surg.* 1995;112(3): 391-398.
- Faur AC, Sas I, Motoc AG, et al. Ki-67 and p53 immunostaining assessment of proliferative activity in salivary tumors. *Rom J Morphol Embryol.* 2015;56(4):1429-1439.