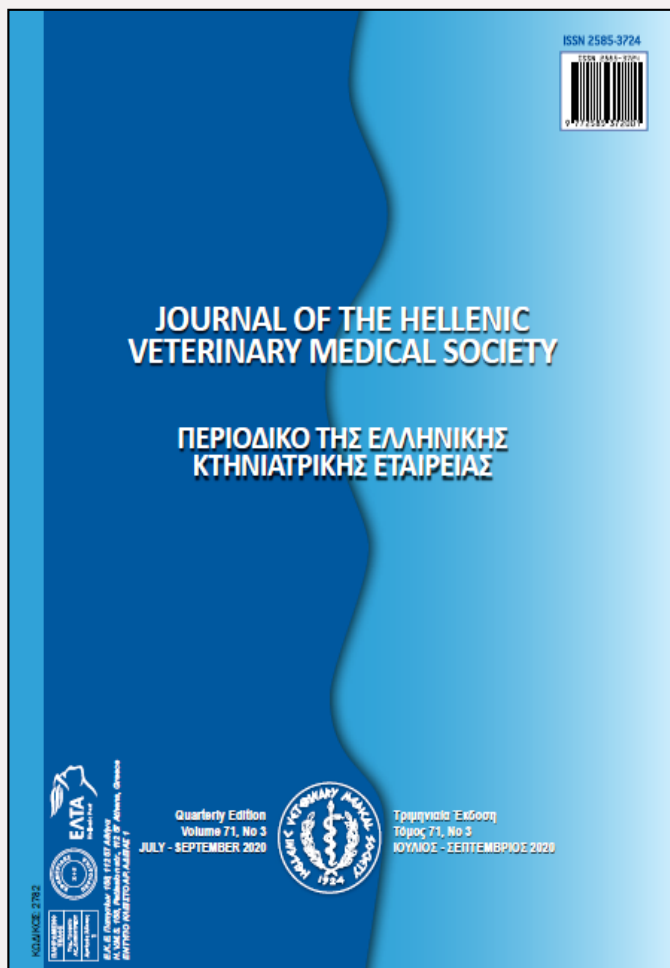


Journal of the Hellenic Veterinary Medical Society

Vol. 71, 2020



Malignant fibrous histiocytoma in a budgerigar (*Melopsittacus undulatus*)

- ÖZEN H. Department of Pathology,
Faculty of Veterinary
Medicine, Balıkesir
University, Balıkesir, Turkey
- DAĞ S. Department of Pathology,
Faculty of Veterinary
Medicine, Kafkas University,
Kars, Turkey
- KARAKURT E. Department of Pathology,
Faculty of Veterinary
Medicine, Kafkas University,
Kars, Turkey
- BÜYÜK E. Institute of Medical
Sciences, Kafkas University,
Kars, Turkey

<https://doi.org/10.12681/jhvms.25105>

Copyright © 2020 H. ÖZEN, S. DAĞ, E.
KARAKURT, E. BÜYÜK



To cite this article:

ÖZEN, H., DAĞ, S., KARAKURT, E., & BÜYÜK, E. (2020). Malignant fibrous histiocytoma in a budgerigar (*Melopsittacus undulatus*). *Journal of the Hellenic Veterinary Medical Society*, 71(3), 2407-2412.
doi:<https://doi.org/10.12681/jhvms.25105>

Malignant fibrous histiocytoma in a budgerigar (*Melopsittacus undulatus*)

H. Özen¹, S. Dağ², E. Karakurt², E. Büyük³

¹ Department of Pathology, Faculty of Veterinary Medicine, Balıkesir University, Balıkesir, Turkey

² Department of Pathology, Faculty of Veterinary Medicine, Kafkas University, Kars, Turkey

³ Institute of Medical Sciences, Kafkas University, Kars, Turkey

ABSTRACT. In this report, a case of malignant fibrous histiocytoma in a budgerigar (*Melopsittacus undulatus*) is described. At necropsy, a tumorous subcutaneous mass was noted to be located under the right wing at the level of humerus in a budgerigar. On microscopic examination, the tumor was composed of pleomorphic cells having mostly round to oval large nucleus. Presence of occasional bands composed of fibroblastoid cells were noted. Occasional giant cells and mitotic figures were also observed. Based on the microscopic findings, a diagnosis of malignant fibrous histiocytoma was made. The present case in an exotic bird was found to be interesting, since malignant fibrous histiocytomas are rare tumors of domestic animals and mostly seen in dogs.

Keywords: Budgerigar, pleomorphic sarcoma, malignant fibrous histiocytoma, histopathology

Corresponding Author:
Hasan Özen, Department of Pathology, Faculty of Veterinary Medicine,
Balıkesir University, Balıkesir, Turkey
E-mail address: hasanozen@hotmail.com

Date of initial submission: 18-11-2019
Date of revised submission: 03-06-2020
Date of acceptance: 10-07-2020

INTRODUCTION

Malignant fibrous histiocytoma (MFH), in a simplified term, can be defined as an entity of undifferentiated pleomorphic sarcoma. MFH is accepted as a descriptive morphologic term and not reflects the cellular origin of the tumor (Gross et al., 2005). Debate over nomenclature of these tumors continues due to unidentified origin of the tumor cells and the various histomorphologic patterns they present. The term malignant fibrous histiocytoma was first described by O'Brien and Stout (1964) and some other names such as giant cell tumor of soft parts, dermatofibrosarcoma protuberans, malignant xanthogranuloma and reticulum cell sarcoma of soft tissues, malignant fibrous xanthoma, fibrous xanthoma were used for undifferentiated pleomorphic sarcomas (Roffe, 1987). MFH is the most common sarcoma of extremities in human, and mostly seen in soft tissues although can also be located in bones, various organs and regions of the body (Fletcher, 1992; Schneider et al., 1999). They are mostly encountered in elderly people though can also be seen in young, with a mean age of 54 years in a study population. (Gibbs et al., 2001). In the animal kingdom, dogs are the most commonly reported animals with MFH. These tumors, as in human, have been reported in older pets but can also be seen in younger ages (Pires, 1997; Do et al., 2009). Cases of MFH were reported in a number of animal species, such as mouse, rat, cat, dog, opossum, cattle, horse and birds (Schneider et al., 1999).

MFHs are highly aggressive tumors with a rapid clinic progression and poor prognosis (Gibbs et al.,

2001). Five subtypes of MFH were described in human; storiform-pleomorphic, giant cell, inflammatory, myxoid and angiomatoid, however the last one is no longer considered under MFH (Al-Agha and Igbokwe, 2008). In animals, only storiform-pleomorphic and giant cell subtypes were reported to be present, though inflammatory form is still controversial (Do et al., 2009; Hendrick, 2017; Al-Agha and Igbokwe, 2008). The most common morphologic type of MFHs has a background of pleomorphic spindle-shaped cells haphazardly organized or in storiform pattern (Kerlin and Hendrick, 1996). In MFHs, inflammatory and giant cells can be present in varying numbers. These tumors are grossly noted as firm gray-white masses and show variable metastatic potential depending on the case (Hendrick, 2017). Since MFH is a rare tumor in animals and only few previous reports are currently present in birds, one in a mallard (Roffe, 1987) and the other in a pigeon (Derakhshanfar and Oloumi, 2008), a case of MFH detected in a budgerigar was thought to worth to report.

CASE HISTORY

The study material was an adult female budgerigar (*Melopsittacus undulatus*) brought to the Department of Pathology, Faculty of Veterinary Medicine, Kafkas University in order to define the cause of death. Systemic necropsy was performed, gross and microscopic findings were described. Body condition of the bird was quite weak. A firm white to grey subcutaneous mass of 2x1x1 cm was noted under the right wing, at the level of humerus (Figure 1). No other masses were noted at any organs and no other pathological changes were seen as well. The mass was routinely fixed in formalin and paraffin embedded, and the sections cut from the paraffin blocks were stained with hematoxylin and eosin (H&E) and viewed under a light microscope.



Figure 1. A nodular subcutaneous mass in the budgerigar

In microscopic view, pleomorphic mostly round to oval shaped cells having round to oval nucleus with dense chromatin at nuclear periphery were observed (Figure 2). The cells were mostly haphazardly located. Spindle shaped fibroblastoid cells trying to form weak bundles and few inflammatory cells were recognizable within the tumor mass, which had

patchy zones of scarce collagenous stroma. Moderate levels of anisocytosis and anisokaryosis were notable (Figure 3). Moderate number of giant cells containing 3 to 10 nuclei with mostly peripheral localization was recognizable (Figure 2). Low to high number of mitotic figures depending on the viewed area were recorded (Figure 3).

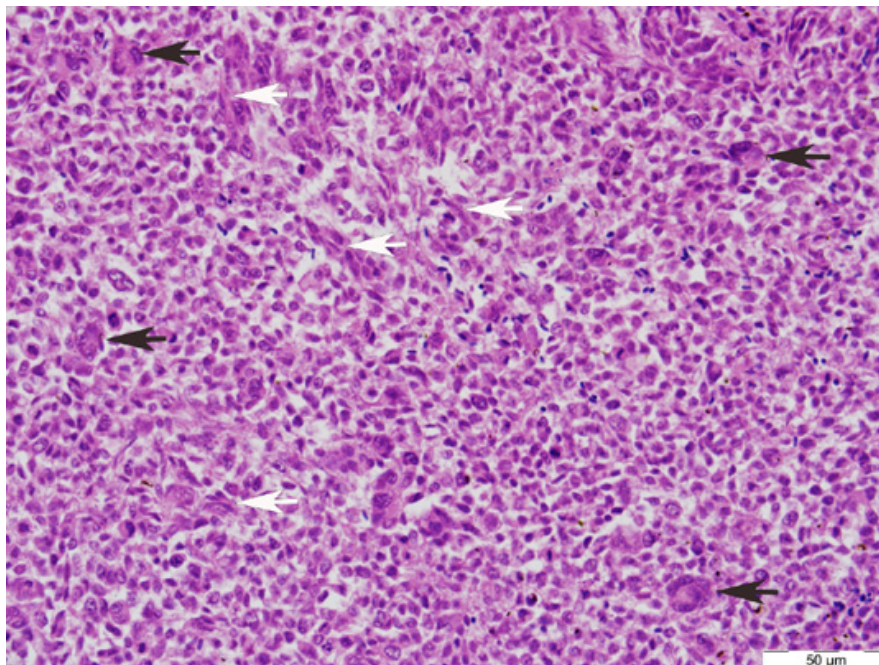


Figure 2. Microscopic image of the tumor consisting of mostly pleomorphic cells, bands of fibroblastoid cells (white arrows) and giant cells (black arrows), H&E

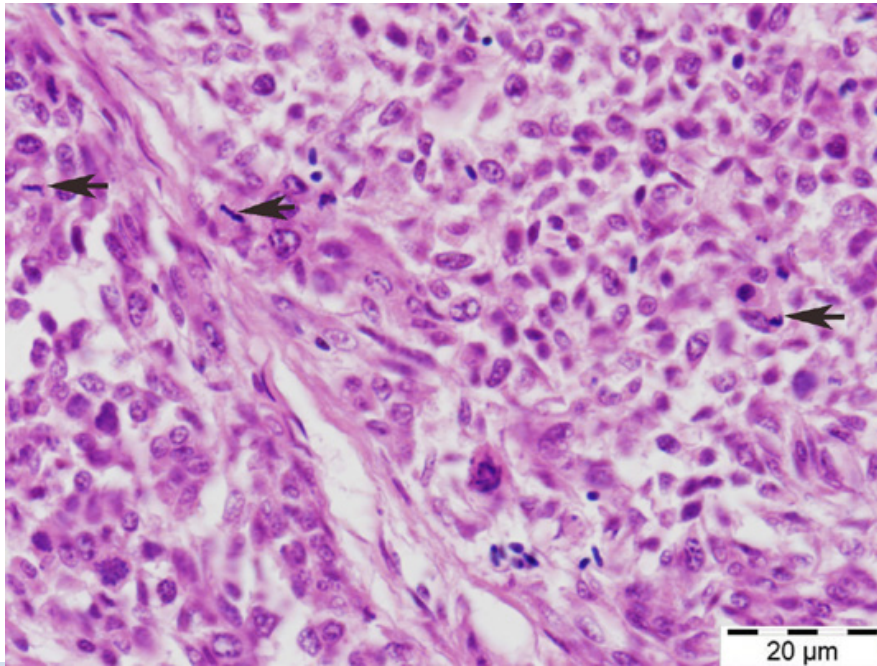


Figure 3. Pleomorphic cells showing anisocytosis and anisokaryosis. Mitotic figures are prominent (arrows), H&E

DISCUSSION

Neoplasia occurs with changing frequencies in companion birds and seems to increase with age as in mammals. A variety of tumors are encountered in these pet birds (Reavill, 2004). Among the pet birds, budgerigars are one of the most common animals that neoplastic lesions detected probably due to the widespread occupancy of this pet as well as better care conditions causing longer lifespan. Cutaneous and subcutaneous lesions happen to comprise a significant place within all tumors in exotic birds (Reavill, 2004). In an investigation, skin tumors were reported to comprise of 57% of all tumors in budgerigars (Sutherland et al., 2016). Among the skin tumors, malignant fibrous histiocytoma is a rare tumor of animals. These tumors are known to be the most common soft tissue sarcomas in humans (Zagars et al., 1996). In domestic animals, MFH is seen most commonly in dogs and occurrence of MFH in birds or poultry animals is quite rare. With this presentation, a case of MFH was described in a budgerigar with its gross and histopathology views as reference to the current knowledge of these tumors.

In domestic animals, MFHs can be viewed in three subtypes namely storiform-pleomorphic, giant cell and inflammatory (Do et al., 2009; Al-Agha and

Igbokwe, 2008; Kiran et al., 2005). However, occurrence of inflammatory subtype in domestic animals remains controversial (Hendrick, 2017). MFHs are generally described as nodular, white to gray firm masses located mostly subcutaneously. However, various organ localizations such as spleen, kidney, liver, lung, lymph nodules and bones were also described in animals (Kerlin and Hendrick, 1996). In this current case, consistent with the general gross appearance and localization, a grey-white firm nodular mass located subcutaneously in the right wing was also recorded. MFHs are known to be quite aggressive and locally invasive tumors and may metastasize to other organs, though tendency to make metastasis may show great variation from case to case (Gibbs et al., 2001). In the current case, as in similar to most MFH cases, no metastasis to other organs were noted and the tumor was a subcutaneously located unencapsulated circumscribed solitary mass.

Histomorphology of MFHs depends on the subtypes, and spindle-shaped cells mixed with histiocytes dominates the tumor mass and mostly shows storiform or whirling pattern (Hendrick, 2017). Inflammatory cells and giant cells can also be present in varying numbers and in some cases depending on the subtype may dominate the field, naming the tu-

mor as inflammatory or giant cell subtype of MFH, respectively. Occasionally, parts of tumor mass may present different views making it difficult to name it as one or the other subtype (Kerlin and Hendrick, 1996). In the current case, pleomorphic cells having mostly round to oval nucleus intermixed with spindle shaped fibroblastoid cells were noted. The tumor cells were mostly located haphazardly, however some forms of storiform pattern was also noted. Occasional inflammatory cells and giant cells containing few nuclei were observed throughout the tumorous mass. Since these cells did not dominate the field, inflammatory and giant cell subtypes for MFH was eliminated. In giant cell type of MFH, mostly osteoclastoid giant cells were described (Ko et al., 2013), and in the present case the giant cells did not show resembles to such giant cells and mostly recognized as giant cells having 3-10 vesicular nuclei that are located peripherally within the abundant eosinophilic cytoplasm. Some larger cells with a single vesicular large nucleus and scarce cytoplasm were also scattered throughout the section. General view of the tumor was greatly consistent with the storiform-pleomorphic subtype of MFH. In human and domestic animals storiform-pleomorphic subtype was also reported to be the most common among MFHs (Schneider et al., 1999; Hendrick, 2017).

Mostly high mitotic index was described in MFHs (Ko et al., 2013), however reports of MFHs with low mitotic index were also present (Kim et al., 2018). In the current case, low to high mitotic figures showing changes in number from field to field were seen in the tumor mass.

The origin of tumor cells in MFHs is mostly unknown or undetermined. Primitive mesenchymal stem cells, fibroblastoid cells and fibroblasts were suggested as the origin of the tumor and histiocytes are accepted as not to be the neoplastic component of the tumor and be only reactive cells (Schneider et al., 1999). Takeya et al. (1995) suggested that these tumors do not contain histiocytes or macrophages and hence pleomorphous sarcoma might be a better term to name them since the mesenchymal cells differentiating toward fibroblasts may promote monocytes yielding the infiltration of macrophages in these tumors. Weak storiform formation and presence of highly pleomorphic cells in the current case may be considered in this concept and the tumor might only be named as pleomorphous sarcoma, however the term is not used commonly.

Immunohistochemistry has been occasionally performed to distinguish the cell types and to determine the origin of cells. Vimentin positivity to show mesenchymal origin has been seen giving only limited information about the tumor. Markers such as CD11, CD18 and CD68 were also used for monocytic-histiocytic origin, however such attempts for differential diagnosis is yet not completely successful (Ko et al., 2013; Hendrick, 2017; Zimmerman et al., 2019). Therefore, immunohistochemistry still provides limited information about these tumors. However, vimentin only positivity without any other specific or distinct expression of cell line markers were suggested as to name the tumor MFH (Ko et al., 2013). Moreover, technical difficulties in immunohistochemical applications on bird tissues also limits the validity of the technique for differential diagnosis in these animals. In these animals, S-100 for epidermal differentiation, pan-cytokeratin for epithelial, vimentin for mesenchymal, desmin for muscle, and NSE for neuronal origin were used in some frequencies (Garner et al., 2009; Zehnder et al., 2016).

In conclusion, a case of MFH detected in a budgerigar was described with this presentation. Gross and microscopic features of the tumor greatly coincided with the storiform-pleomorphic type of MFH. However, the tumor cells showed mostly haphazard localisation instead of storiform appearance. MFHs are accepted to contain both histiocytic and fibroblastic components and the origin of tumor cells remains still controversial.

ACKNOWLEDGMENTS

This study was presented as a poster in 8th National Veterinary Pathology Congress (1-3 September 2016, Samsun-Turkey).

CONFLICT OF INTEREST

The authors declare no conflicts of interest.

REFERENCES

- Al-Agha OM, Igbokwe AA (2008) Malignant fibrous histiocytoma - Between the past and the present. *Arch Pathol Lab Med* 132: 1030-1035.
- Derakhshanfar A, Oloumi MM (2008) Malignant fibrous histiocytoma in a pigeon. *Iran J Vet Surg* 3: 91-95.
- Do SH, Hong IH, Park JK, Ji AR, Kim TH, Kwak DM, Jeong KS (2009) Two different types of malignant fibrous histiocytomas from pet dogs. *J Vet Sci* 10: 169-171.
- Fletcher CDM (1992) Pleomorphic malignant fibrous histiocytoma: Fact or fiction? *Am J Surg Pathol* 16: 213-228.
- Garner MM, Latimer KS, Mickley KA, Ritzman TK, Nordhausen RW (2009) Histologic, Immunohistochemical, and Electron Microscopic Features of a Unique Pulmonary Tumor in Cockatiels (*Nymphicus hollandicus*): Six Cases. *Vet Pathol* 46: 1100-1108.
- Gibbs JF, Huang PP, Lee RJ, McGrath B, Brooks J, McKinley B, Driscoll D, Kraybill WG (2001) Malignant fibrous histiocytoma: An institutional review. *Cancer Invest* 19: 23-27.
- Gross TL, Ihrke PJ, Walder EJ, Affolter VK (2005) Other mesenchymal tumors. In: *Skin Diseases of the Dog and Cat: Clinical and Histopathologic Diagnosis*. 2nd ed, Blackwell Publishing, Ames, IA: pp 797-812.
- Hendrick MJ (2017) Mesenchymal tumors of the skin and soft tissues. In: Meuten D.J. (ed) *Tumors in Domestic Animals*. Iowa, John Wiley & Sons Inc, USA, pp. 142-175.
- Kerlin RL, Hendrick MJ (1996) Malignant fibrous histiocytoma and malignant histiocytosis in the dog - Convergent or divergent phenotypic differentiation? *Vet Pathol* 33: 713-716.
- Kim JH, Kim HJ, Lee SJ, Yoon HY (2018) Splenic malignant fibrous histiocytoma with concurrent hypertension and epistaxis in an Alaskan malamute dog. *BMC Vet Res* 14: 235.
- Kıran MM, Karaman M, Hatipoğlu F, Koc Y (2005) Malignant fibrous histiocytoma in a dog: A case report. *Vet Med Czech* 50: 553-557.
- Ko JS, Kim, HJ, Choi YM, Kim JW, Park C, Do SH (2013) Diagnostic approach to malignant fibrous histiocytomas of soft tissue in dogs: A case report. *Vet Med-Czech* 58: 621-627.
- O'Brien JE, Stout AP (1964) Malignant fibrous xanthomas. *Cancer* 17: 1445-1458.
- Pires MA (1997) Malignant fibrous histiocytoma in a puppy. *Vet Rec* 140: 234-235.
- Reavill DR (2004) Tumors of pet birds. *Vet Clin Exot Anim* 7: 537-560.
- Roffe TJ (1987) An unusual pleomorphic sarcoma in a hybrid mallard. *J Wildl Dis* 23: 334-337.
- Schneider P, Busch U, Meister H, Qasem Q, Wunsch PH (1999) Malignant fibrous histiocytoma (MFH). A comparison of MFH in man and animals. A critical review. *Histol Histopathol* 14: 845-860.
- Sutherland M, Ploeg R, Sacks P, Macwhirter P (2016) Avian lumps and bumps: clinical and histological findings associated with avian tumours, a preliminary review. Association of Avian Veterinarians Australasian Committee Ltd. Annual Conference, Brisbane, Queensland, Australia: pp 37-45.
- Takeya M, Yamashiro S, Yoshimura T, Takahashi K (1995) Immunophenotypic and immunoelectron microscopic characterization of major constituent cells in malignant fibrous histiocytoma using human cell lines and their transplanted tumors in immunodeficient mice. *Lab Invest* 72: 679-688.
- Waters CB, Morrison WB, Denicola DB, Widmer WR, White MR (1994) Giant cell variant of malignant fibrous histiocytoma in dogs: 10 cases (1986-1993). *J Am Vet Med Assoc* 205: 1420-1424.
- Zagars GK, Mullen JR, Pollack A (1996) Malignant fibrous histiocytoma: outcome and prognostic factors following conservation surgery and radiotherapy. *Int J Radiat Oncol Biol Phys* 34: 983-994.
- Zehnder A, Graham J, Reavill DR, McLaughlin A (2016) Neoplastic Diseases in Avian Species. In: *Current Therapy in Avian Medicine and Surgery*. 1st ed, Elsevier Inc, St. Louis, MO: pp 107-141.
- Zimmerman K, Almy F, Saunders G, Crisman M, Leomanrdi L (2019) An unusual case of giant cell tumor of soft parts in an American Warmblood horse. *Open Vet J* 9: 44-48.