

1-1-2021

Tendon of Flexor Carpi Radialis in carpal tunnel: a radiologic and cadaveric study

BURCU ERÇAKMAK GÜNEŞ

ALPER VATANSEVER

MEHMET DENİZ DEMİRYÜREK

KADRIYE MİNE ERGUN

MEHMET HAKAN ÖZSOY

Follow this and additional works at: <https://dctubitak.researchcommons.org/medical>



Part of the [Medical Sciences Commons](#)

Recommended Citation

GÜNEŞ, BURCU ERÇAKMAK; VATANSEVER, ALPER; DEMİRYÜREK, MEHMET DENİZ; ERGUN, KADRIYE MİNE; and ÖZSOY, MEHMET HAKAN (2021) "Tendon of Flexor Carpi Radialis in carpal tunnel: a radiologic and cadaveric study," *Turkish Journal of Medical Sciences*: Vol. 51: No. 4, Article 41. <https://doi.org/10.3906/sag-2012-31>

Available at: <https://dctubitak.researchcommons.org/medical/vol51/iss4/41>

This Article is brought to you for free and open access by TÜBİTAK Academic Journals. It has been accepted for inclusion in Turkish Journal of Medical Sciences by an authorized editor of TÜBİTAK Academic Journals.

Tendon of Flexor Carpi Radialis in carpal tunnel: a radiologic and cadaveric study

Burcu ERÇAKMAK GÜNEŞ^{1*}, Alper VATANSEVER², Deniz DEMİRYÜREK¹, Mine ERGUN¹, Hakan ÖZSOY³

¹Department of Anatomy, Faculty of Medicine, Hacettepe University, Ankara, Turkey

²Department of Anatomy, Faculty of Medicine, Balıkesir University, Balıkesir, Turkey

³Department of Orthopedy and Traumatology, Memorial Hospital, Ankara, Turkey

Received: 03.12.2020 • Accepted/Published Online: 02.03.2021 • Final Version: 30.08.2021

Background/aim: Carpal tunnel is an important anatomical passage that carries the flexor tendons into the hand. As there is still no consensus about its contents among the anatomy textbooks, the main purpose of this study was to identify the relations of the flexor carpi radialis tendon in the carpal tunnel.

Materials and methods: This retrospective study was completed in April 2018 at authors' university's hospital. Seventy-four female and 44 male patients' wrists without any pathology were examined by using magnetic resonance images. The series of axial sections where the pisiform exist were evaluated by using T1 sequence and the structures in the carpal tunnel were identified.

Results: Results of this study showed that the tendon of the flexor carpi radialis was found above the flexor retinaculum within its own septal compartment in all patients.

Conclusion: According to the results, tendon of flexor carpi radialis crosses the wrist region superficial to the carpal tunnel. Thus, tendon of flexor carpi radialis doesn't have any effect on the carpal tunnel syndrome. Further cadaveric studies would be useful for identifying the contents of the carpal tunnel and morphological organization of the wrist.

Key words: Cadaver, carpal tunnel, flexor carpi radialis, magnetic resonance imaging, wrist anatomy

1. Introduction

The antebrachial fascia, anteriorly, is continuous superficially as palmar carpal ligament and distally and deeply as a strong fibrous band; the flexor retinaculum (transverse carpal ligament) [1,2]. At the medial aspect of the wrist, ulnar artery and nerve pass through a tunnel between these ligaments, which is termed as the ulnar tunnel (guyon canal) [3]. The roof and floor of the canal is bordered by palmar carpal ligament and transvers carpal ligament, respectively [1-3]. Thick flexor retinaculum also encloses the carpal groove superiorly and forms a passageway on the palmar side of the wrist [4,5]. The carpal tunnel is an osseo-fibrous tunnel which is bordered superiorly by transverse carpal ligament and the base consist of the hook of hamate, triquetrum, and pisiform bones medially; scaphoid and the trapezium bones laterally [4,6,7]. The tendons of the flexor muscles of the fingers and the median nerve pass through the tunnel [2,4,5,7]. Most of the textbooks mentioned that 10 structures traverse the tunnel including the 9 tendons which are flexor digitorum superficialis and profundus, and palmaris longus and the median nerve [1,4,5,7,8]. On the anterior surface of the

wrist, the flexor retinaculum and palmar carpal ligament held the tendons of the flexor muscles in the tunnel [9]. The tendon of the flexor carpi radialis (FCRt) passes through a vertical groove on the trapezium within its own tunnel at the wrist region, which is separated from the carpal tunnel by the deep portion of the transverse carpal ligament and inserts on the palmar surface of the base of the second and third metacarpal [1,8-11]. In addition to this well-known information, it is also mentioned that FCRt found within the carpal tunnel in its own tunnel [8]. Previous studies have focused on describing the carpal tunnel's borders and related structures by using different methods to identify the safe zones for carpal tunnel release [12-14]. MRI and ultrasound methods are used for identification of the course of FCRt and diagnosing the wrist pathologies [15-18]. Carpal tunnel syndrome is the most common entrapment neuropathy characterized by tingling, burning, pain, and paresthesia in the first 3 radial digits and radial half of the forth digit due to the compression of the median nerve in the carpal tunnel [19-22]. Although it has been widely studied, while mentioning the contents of the carpal tunnel, differences could be seen among the

* Correspondence: burcue@hacettepe.edu.tr

textbooks [1,2,8,23–26]. There is no conflict about the fact that the tendons of flexor digitorum superficialis, flexor digitorum profundus, flexor pollicis longus, and the median nerve are located inside the carpal tunnel. The presence of the tendon of flexor carpi radialis in the tunnel could be confusing. The aim of this study is to reveal the relationship between FCRT and carpal tunnel. Thus, the borders and contents of the carpal tunnel could be described easily. Results of this study could make an important contribution to the literature and support the diagnostic studies about carpal tunnel syndrome.

2. Materials and methods

This study was carried out in pursuit of receiving the ethical approval from the local ethics committee (GO 17/887-15) and completed according to the principles of the Helsinki Declaration.

2.1. Participants

Retrospectively, 118 (74 female and 44 male) wrist regions MRI scans were evaluated. None of the patients had surgery or trauma history. Patients with wrist pathology were excluded. The mean age of the patients was 35.7 (range: 9–74). In addition, 3 fresh-frozen upper limb cadavers were dissected to demonstrate the course of the flexor carpi radialis tendon.

2.2. Image acquisition

Wrist MRI evaluations were completed using any of three 1.5 Tesla scanners in the radiology department (SymphonyTim, Siemens Healthcare; Achieva, Philips Healthcare; Signa HDxt, GE Healthcare). MRI protocols were performed while patients were in the supine position. The radiology department's routine MRI protocol consisted of coronal, sagittal, and transverse T2-weighted spin-echo and sagittal and transverse T1-weighted spin-echo with 3.0–3.5 mm slice thickness. All patients' MRI series were obtained from the Picture Archiving and Communication System (PACS) at authors' university hospital. All evaluations were completed by a 20 year experienced anatomy professor, a 15-year experienced anatomy specialist, a 6-year experienced anatomy specialist and a 20-year experienced orthopedic associated professor by using Osirix-Lite version 9 (Pixmeo, SARL, Switzerland).

2.3. Parameters

To standardize the evaluation, the series of axial sections from the level of pisiform bone were examined. First location of the FCRT, proximally to the carpal tunnel was detected. Afterward the course of the tendon was followed till it passed through the carpal tunnel and its location according to the flexor retinaculum was observed. While dissecting the fresh-frozen cadavers, first incision was applied vertically from the anterior surface of the

middle of the forearm to the proximal part of the palmar surface of the hand. The skin and superficial connective tissues were deviated carefully to view the muscle groups of the anterior compartment of forearm and the flexor retinaculum. The entire course of tendons of the flexor muscles were evaluated.

3. Results

In all MRI series the flexor tendons of the digits and median nerve were located below the flexor retinaculum while the FCRT was located above the flexor retinaculum within its own septal compartment (Figure 1). Likewise, the cadaveric dissections also executed that the flexor tendons of digits and median nerve were covered by flexor retinaculum within the carpal tunnel and, a completely different and separated compartment of the FCRT was found above the flexor retinaculum (Figure 2 and Figure 3).

4. Discussion

At wrist region distal continuation of the antebrachial fascia forms superficially the palmar carpal ligament and deeply the flexor retinaculum (transverse carpal ligament) [1,2]. Between palmar carpal ligament and flexor retinaculum Guyon canal is found which includes ulnar artery and nerve [3]. Strong fibrous flexor retinaculum forms the roof of the carpal tunnel [7,12]. It is important to define the flexor retinaculum's boundaries precisely to identify the contents of carpal tunnel. Furthermore, this will lead to creating common terminology between the anatomy and clinical sciences. The FCR muscle is found at the anterior compartment of the forearm and mainly flexes and to a lesser extent radially rotates the wrist [16]. Although its morphological and clinical importance has been widely studied, there is still no consensus about its relationship with the carpal tunnel [1,2,8,9,23–26]. Most of the textbooks mentioned that 10 structures traverse the tunnel including the 9 tendons including flexor digitorum superficialis and profundus, and palmaris longus and the median nerve [1,4,5,7,8]. However, some other textbooks mention that the FCRT found in the tunnel [8].

Morphological studies have demonstrated that the FCRT was not included in the contents of the carpal tunnel [6,16,27–29]. Chamas et al. described as FCRT forms the lateral border of the carpal tunnel in a morphological study that focused on the explaining the boundaries of carpal tunnel [7]. The FCRT is covered by a fibro-osseous tunnel which is adjacent to the flexor retinaculum of the carpal tunnel [4,10]. This tunnel is formed proximally by the scaphoid, the flexor retinaculum, and a vertical retinacular septum and, distally, by trapezium, again the flexor retinaculum, and the vertical retinacular septum [10]. This vertical retinacular septum separates the FCRT from the carpal tunnel [10,16,30]. Also, it is usually used

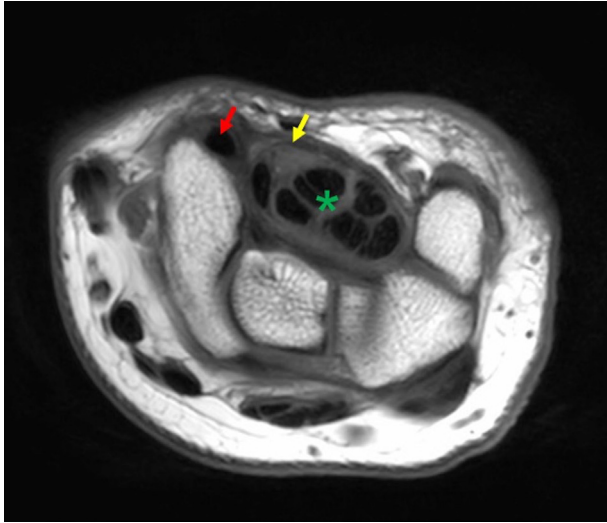


Figure 1. An MRI section demonstrating flexor carpi radialis tendon's relation with the carpal tunnel. Red arrow; the tendon of flexor carpi radialis. Yellow arrow; flexor retinaculum. Green asterix; tendons of flexor digitorum superficialis and profundus with in the carpal tunnel.

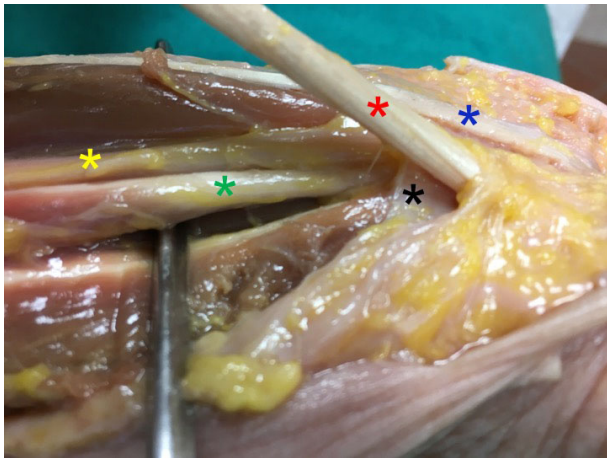

Figure 2. Dissection of the wrist joint. Black asterix; flexor retinaculum. Red asterix; tendon of flexor carpi radialis. Blue asterix; tendon of palmaris longus. Yellow asterix; median nerve. Green asterix; tendon of flexor pollicis longus muscle.

as donor in tendon transfers and reconstructive surgeries of the forearm [22,31]. Due to this proximity, any disorder like tenosynovitis of the FCRT may imitate carpal tunnel syndrome [10]. Therefore, FCR tenosynovitis should be considered in the differential diagnosis of carpal tunnel syndrome and a detailed examination should be performed.

According to the results of this study, the FCRT crosses the wrist superficial to the carpal tunnel. Thus, the FCRT

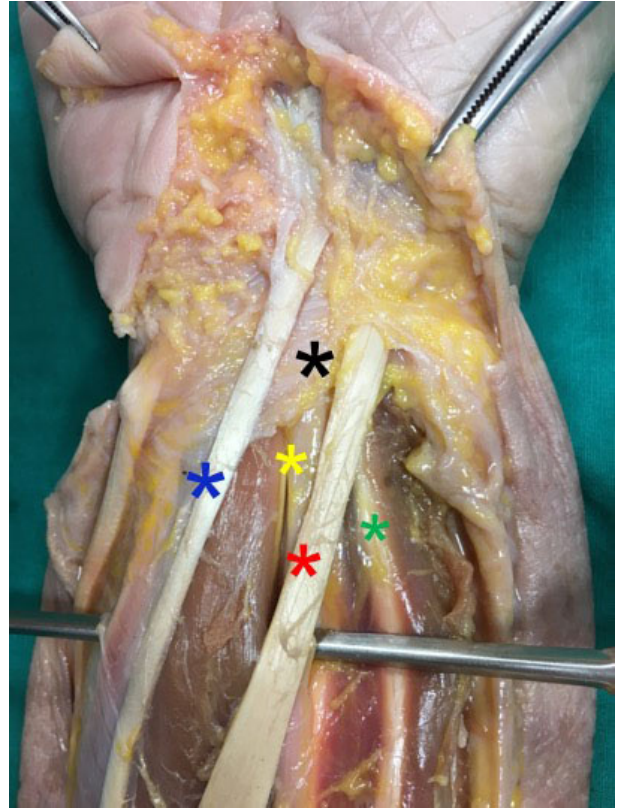


Figure 3. Separate compartment of the flexor carpi radialis tendon. Red asterix; the tendon of flexor carpi radialis. Black asterix; the flexor retinaculum. Blue asterix; palmaris longus muscle. Yellow asterix; median nerve. Green asterix; tendon of flexor pollicis longus muscle.

may not be included as a factor in the etiology of the carpal tunnel syndrome but the close relationship must be in mind that the pathologies may imitate the carpal tunnel syndrome. Further multidisciplinary studies would be useful for identifying the contents of the carpal tunnel, the morphological organization of the wrist, and the biomechanical etiologies and mechanisms of the carpal tunnel syndrome.

Although, the well-known theoretical information about the carpal tunnel, there is still no consensus about situation of the FCRT in major anatomy textbooks. Therefore, this study was demonstrated the precise situation of the tendon of the flexor carpi radialis with the carpal tunnel. Results verified that the FCRT does not pass through the carpal tunnel, but it passes through its own compartment that is formed by the flexor retinaculum. The main limitation of the present study was the lack of cadaveric measurements due to the insufficient number of specimens. Moreover, a histological investigation should be performed to understand the course of the flexor retinaculum.

Acknowledgments

This research did not receive any specific grant from funding agencies in the public, commercial, or not-for-profit sectors. The authors would like to thank for their hospital's Radiology Department's staff for their support for presented study.

Acknowledgement/Disclaimers/Conflict of interest

The authors declare that they have no conflict of interest. The abstract of the manuscript was not presented in any other public conferences.

References

1. Standring S. *Gray's Anatomy: The Anatomical Basis of Clinical Practice*. 41th ed. London, UK: Elsevier Limited; 2016. pp. 863-864.
2. Moore KL DA, Agur AMR. *Clinically Oriented Anatomy*. 7th ed. Philadelphia, USA: Wolters Kluwer/Lippincott Williams & Wilkins Health; 2014. pp. 688-689.
3. Strohl AB, Zelouf DS. Ulnar tunnel syndrome, radial tunnel syndrome, anterior interosseous nerve syndrome, and pronator syndrome. *Journal of American Academy of Orthopedic Surgery* 2017; 25 (1): e1-e10. doi:10.5435/JAAOS-D-16-00010
4. Brooks R, Kistler A, Chowdhry S, Swiergosz A, Perlin K et al. Anatomic landmarks to locate the median nerve for safe wrist block or carpal tunnel steroid injection. *Eplasty* 2019; 19: 139-146.
5. Marquardt TL, Gabra JN, Li ZM. Morphological and positional changes of the carpal arch and median nerve during wrist compression. *Clinical Biomechanics (Bristol, Avon)* 2015; 30 (3): 248-253. doi:10.1016/j.clinbiomech.2015.01.007
6. Bijannejad D, Azandeh S, Javadnia F, Gholami MR, Gharravi AM et al. Persistent median artery in the carpal tunnel and anastomosis with superficial palmar arch. *Case Reports Plastic Surgery Hand Surgery* 2016; 3 (1): 25-27. doi:10.3109/23320885.2016.1166964
7. Chammas M, Boretto J, Burmann LM, Ramos RM, Dos Santos Neto FC et al. Carpal tunnel syndrome - part 1 (anatomy, physiology, etiology and diagnosis). *Revista Brasileira de Ortopedia (English Edition)* 2014; 49 (5): 429-436. doi:10.1016/j.rboe.2014.08.001
8. Sinnatamby CS. *Last's Anatomy: Regional and Applied*. 12th ed. Elsevier Health Sciences; 2011. pp. 64-66.
9. Moore KL DA, Agur AMR. *Clinically Oriented Anatomy*. 7th ed. Philadelphia, USA: Wolters Kluwer/Lippincott Williams & Wilkins Health; 2014. pp. 747-749.
10. Bolles CL, Abdella A, Battaglia PJ. Flexor carpi radialis tenosynovitis mimicking carpal tunnel syndrome diagnosed and monitored with ultrasound: case report. *SN Comprehensive Clinical Medicine* 2020; 2 (6): 797-801. doi:10.1007/s42399-020-00320-1
11. Rotman MB, Donovan JP. Practical anatomy of the carpal tunnel. *Hand Clinics* 2002; 18 (2): 219-230. 10.1016/s0749-0712(01)00003-8
12. Manley M, Boardman M, Goitz RJ. The carpal insertions of the transverse carpal ligament. *Journal of Hand Surgery* 2013; 38 (4): 729-732. doi:10.1016/j.jhsa.2013.01.015
13. Pensy RA, Brunton LM, Parks BG, Higgins JP, Chhabra AB. Single-incision extensile volar approach to the distal radius and concurrent carpal tunnel release: cadaveric study. *Journal of Hand Surgery* 2010; 35 (2): 217-222. doi:10.1016/j.jhsa.2009.11.011
14. Tannan SC, Pappou IP, Gwathmey FW, Freilich AM, Chhabra AB. The extended flexor carpi radialis approach for concurrent carpal tunnel release and volar plate osteosynthesis for distal radius fracture. *Journal of Hand Surgery* 2015; 40 (10): 2026-2031. doi:10.1016/j.jhsa.2015.07.001
15. Elsaman AM, Thabit MN, Radwan AR, Ohrndorf S. Idiopathic carpal tunnel syndrome: evaluation of the depth of the carpal tunnel by ultrasonography. *Ultrasound in Medicine & Biology* 2015; 41 (11): 2827-2835. doi:10.1016/j.ultrasmedbio.2015.06.018
16. Luong DH, Smith J, Bianchi S. Flexor carpi radialis tendon ultrasound pictorial essay. *Skeletal Radiology* 2014; 43 (6): 745-760. doi:10.1007/s00256-014-1846-1
17. McCann PA, Amirfeyz R, Wakeley C, Bhatia R. The volar anatomy of the distal radius--an mri study of the fcr approach. *Injury* 2010; 41 (10): 1012-1014. doi:10.1016/j.injury.2010.02.031
18. Parellada AJ, Morrison WB, Reiter SB, Carrino JA, Kloss LA et al. Flexor carpi radialis tendinopathy: spectrum of imaging findings and association with triscleritis arthritis. *Skeletal Radiology* 2006; 35 (8): 572-578. doi:10.1007/s00256-006-0116-2
19. Zamborsky R, Kokavec M, Simko L, Bohac M. Carpal tunnel syndrome: symptoms, causes and treatment options. Literature Review. *Journal of Ortopedics, Traumatology and Rehabilitation* 2017; 19 (1): 1-8. doi:10.5604/15093492.1232629

20. Koh SH, Kwon BC, Park C, Hwang SY, Lee JW et al. A comparison of the performance of anatomical mri and dti in diagnosing carpal tunnel syndrome. *European Journal of Radiology* 2014; 83 (11): 2065-2073. doi:10.1016/j.ejrad.2014.08.007
21. Newington L, Harris EC, Walker-Bone K. Carpal tunnel syndrome and work. *Best Practice & Research: Clinical Rheumatology* 2015; 29 (3): 440-453. doi:10.1016/j.berh.2015.04.026
22. Hosapatna M, Souza AD, Rao M, Hari Ankolekar V. Morphology and innervation of brachioradialis and flexor carpi radialis and their utility in tendon transfer surgeries: a cadaveric study. *Morphologie* 2020; 104 (345): 91-96. 10.1016/j.morpho.2019.10.046
23. Agur AM, Dalley AF. *Grant's Atlas of Anatomy*. 12th ed. Lippincott Williams & Wilkins; 2009. pp. 554-555.
24. Elhan A, Karahan ST. *Sobotta İnsan Anatomisi Atlası*. 7th ed. Ankara, Turkey: Elsevier; 2011. pp. 176-177.
25. Hansen JT. *Netter's Clinical Anatomy*. 3th ed. Saunders/Elsevier; 2014. p.327.
26. Snell RS. *Clinical Anatomy by Regions*. 9th ed. Wolters Kluwer, Lippincott Williams & Wilkins. 2012. p. 398.
27. Gabra JN, Kim DH, Li ZM. Elliptical morphology of the carpal tunnel cross section. *European Journal of Anatomy* 2015; 19 (1): 49-56.
28. Gabra JN, Li ZM. Carpal tunnel cross-sectional area affected by soft tissues abutting the carpal bones. *Journal of Wrist Surgery* 2013; 2 (102): 73-78. doi:10.1055/s-0032-1329593
29. Won HS, Han SH, Oh CS, Chung IH, Suh JS et al. Morphological study of the proximal boundary of the flexor retinaculum and of its constituent parts. *Journal of Hand Surgery (European Volume)* 2012; 37 (1): 35-41. doi:10.1177/1753193411414515
30. Brink PR, Franssen BB, Disseldorp DJ. A simple blind tenolysis for flexor carpi radialis tendinopathy. *Hand (N Y)* 2015; 10 (2): 323-327. doi:10.1007/s11552-014-9631-0
31. Zhou M, Ishizawa A, Akashi H, Suzuki R, Kanatsu Y et al. An anomalous case of the flexor carpi radialis with an excessive muscular bundle. *Anatomical Science International* 2020; 95 (2): 293-296. doi:10.1007/s12565-019-00519-w