

# Investigation of the effects of post-operative intraperitoneal, oral, and rectal phenytoin administration on colorectal anastomosis in rats

Ali Duran, M.D.,<sup>1</sup> Ferhat Çay, M.D.,<sup>1</sup> Nelin Hacıoğlu, M.D.,<sup>2</sup> Esra Tokay, M.D.,<sup>2</sup>  
 Feray Köçkar, M.D.,<sup>2</sup> Eren Altun, M.D.,<sup>3</sup> Murat Başbuğ, M.D.,<sup>1</sup> Azad Gazi Şahin, M.D.,<sup>1</sup>  
 Hasan Yaşar, M.D.,<sup>1</sup> Uğur Mengeneçi, M.D.,<sup>1</sup> Hüseyin Pülat, M.D.<sup>4</sup>

<sup>1</sup>Department of Surgery, Balıkesir University Faculty of Medicine, Balıkesir-Türkiye

<sup>2</sup>Department of Molecular Biology and Genetics, Balıkesir University Faculty of Sciences and Arts, Balıkesir-Türkiye

<sup>3</sup>Department of Pathology, University of Health Sciences, Bağcılar Training and Research Hospital, İstanbul-Türkiye

<sup>4</sup>Department of General Surgery Clinic, Mersin City Hospital, Mersin-Türkiye

## ABSTRACT

**BACKGROUND:** Anastomotic leakage is the most feared complication after colonic anastomosis. The purpose of the study is to determine the effects of phenytoin applied by different application routes, on the healing process of colorectal anastomoses.

**METHODS:** Wistar Albino rats were divided into Intraperitoneal Phenytoin Group, Oral Phenytoin Group (OAP), Rectal Phenytoin Group (RAP), and control groups. The molecular effect of phenytoin on the expression of vascular endothelial growth factor (VEGF), transforming growth factor-beta (TGF-β), fibroblast growth factor 2 (FGF2), and p53 genes was evaluated at mRNA and protein level. The effects of phenytoin on anastomotic bursting pressure analysis measured as well as pathohistological examinations.

**RESULTS:** There are statistically significant increase in anastomotic bursting pressure values between control and application groups. Inflammatory cell infiltration of all groups increased in the intestinal anastomosis region compared to control. Collagen scores were found to be significantly higher in the OAP and RAP groups compared to the control group. mRNA of TGF-β and FGF2 expression increased in all routes of phenytoin applications.

**CONCLUSION:** Three different administration routes show considerably increase on the bursting pressure. Regarding the results of the expression of FGF2, TGF-β, p53, and VEGF genes, there is a significant increase FGF2 and TGF-β at mRNA and protein level in most administration routes.

**Keywords:** Colorectal anastomoses; epithelization; neovascularization; phenytoin; surgery.

## INTRODUCTION

Anastomotic leaks in colorectal surgery continue to be the most essential and challenging complication, with rates varying between 1% and 30%.<sup>[1-3]</sup> Over the years, many agents have been tried to reduce anastomotic leaks. Phenytoin, which is used in anticonvulsant therapy, has been found to cause gingival hyperplasia in many patients and has been studied in many wound healing models based on this. It has been

shown that phenytoin acts through mechanisms such as an increase in fibroblast proliferation, inhibition of collagenase activity, promotion of collagen distribution, formation of granulation tissue, decrease in bacterial contamination, decrease in wound exudate, and increase in growth factor receptors.<sup>[4,5]</sup>

The aim of this experimental study was to clarify the effects of post-operative administration of phenytoin on the healing process of colorectal anastomoses in rat model. In particu-

Cite this article as: Duran A, Çay F, Hacıoğlu N, Tokay E, Köçkar F, Altun E, et al. Investigation of the effects of post-operative intraperitoneal, oral, and rectal phenytoin administration on colorectal anastomosis in rats. *Ulus Travma Acil Cerrahi Derg* 2022;28:1214-1222.

Address for correspondence: Ali Duran, M.D.

Balıkesir Üniversitesi Tıp Fakültesi, Cerrahi Anabilim Dalı, Balıkesir 10145, Türkiye

Tel: +90 266 - 612 14 61 E-mail: g.cerrahad@gmail.com

*Ulus Travma Acil Cerrahi Derg* 2022;28(9):1214-1222 DOI: 10.14744/tjtes.2022.03704 Submitted: 27.04.2022 Accepted: 29.06.2022

Copyright 2022 Turkish Association of Trauma and Emergency Surgery



lar, we assessed anastomosis by molecular and immunohistochemical analysis as well as bursting pressure and histopathological features of wound healing.

## MATERIALS AND METHODS

### Study Groups and Surgical Procedure

#### Ethical Approval

Ethical approval (2021-4/29.04.2021) was obtained from Balikesir University Animal Experiments Local Ethics Committee for the study.

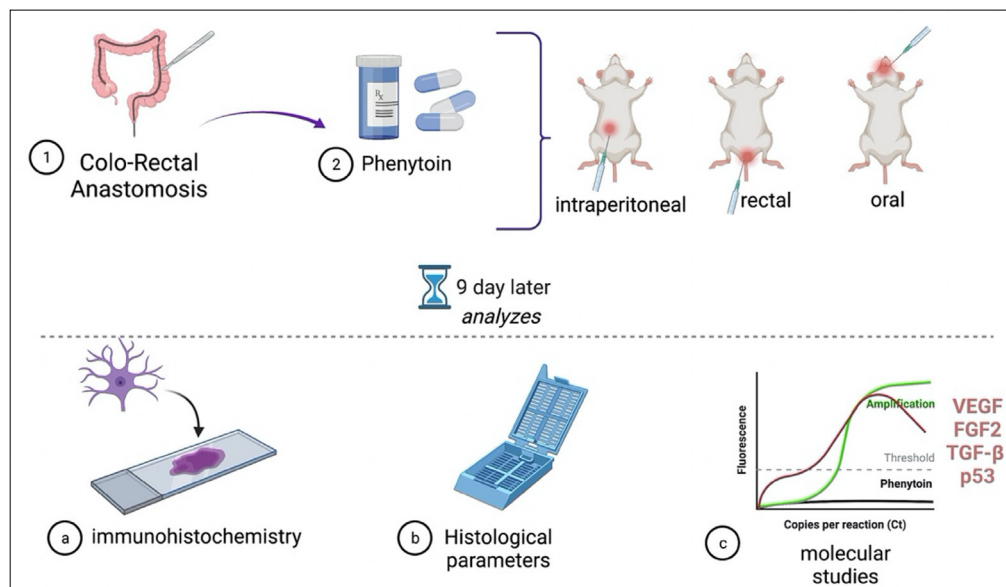
#### Animals and Experimental Design

Forty adult female Wistar Albino rats (weight 260–320 g) were provided by the Balikesir University Experimental Animals Center (Balikesir, Turkey) and were accustomed to laboratory conditions. The animals were housed two per cage at 22–24°C with a 12-h light/dark cycle at 55–60% humidity and were allowed free access to standard rodent chow and water. Four different groups (Groups A-B-C-D) containing ten rats were formed. According to this, Group A: Control Group (n=10), Group B: Intraperitoneal Phenytoin Group (IAP) (n=10), Group C Oral Phenytoin Group (OAP) (n=10), and Group D: Rectal Phenytoin Group (RAP) (n=10) (Fig. 1).

#### Surgical Procedure

All rats fasted for 12 h before surgery, which was performed under sterile conditions. General anesthesia was achieved by intraperitoneally administering 90 mg/kg xylazine hydrochloride (Rompun®, 2% injectable solution 20 mg/mL, Bayer, Canada) and 10 mg/kg ketamine hydrochloride (Ketalar® injectable solution 100 mg/mL Pfizer, UK). After the anterior abdominal wall was shaved, the planned incision line was cleaned with povidone-iodine. Then, the abdomen was entered with a 3 cm vertical midline abdominal incision. The sigmoid colon was

explored, and the intestine was transected. Intestinal tissue samples were taken from all rats for molecular and pathological examination. Samples taken for molecular analysis were placed in RNA-Safe solution, and samples taken for pathology were placed in 10% formaldehyde. Then, anastomosis was performed using the end-to-end anastomosis technique with 5/0 vicryl sutures. After anastomosis, 25–30 mg/kg/day (0.5 mL) phenytoin sodium (Epitoin® injectable solution 250 mg/5 mL Vem, Turkey) intraperitoneally for Group A, 25 mg/kg/day (0.5 mL) phenytoin sodium oral by oral gavage needle for Group B, Group C was given 25 mg/kg/day (0.5 mL) phenytoin sodium rectal with a 4-F rectal tube, and 0.5 mL/day intraperitoneal saline was given to Group D, and the anterior abdominal wall was closed with 4/0 absorbable sutures one by one. After the rats have fasted for 12 h postoperatively, standard diet and drinking water were started. Ketoprofen 2–5 mg/kg 2×1 intramuscular injection was given to rats for post-operative pain. In addition, a single dose of Cefazolin 15–25 mg/kg subcutaneous antibiotic was administered. During the 9 days following the operation, the determined drug doses were administered to all of the study groups. The same amount of physiological saline was applied to the control group. On the 9<sup>th</sup> post-operative day, rats were injected intraperitoneally with 90 mg/kg xylazine hydrochloride (Rompun®, 2% injectable solution 20 mg/mL, Bayer, Canada) and 10 mg/kg ketamine hydrochloride (Ketalar® injectable solution 100 mg/mL Pfizer, England) was administered and general anesthesia was provided. Under anesthesia, the old incision scar was excised and entered into the abdomen. The excised incision scar was bisected and one half was placed in RNA safe solution for molecular analysis and placed at –80°C. The other half was placed in 10% formaldehyde for pathological examination. The anastomosis line was resected with a surgical margin of 2 cm proximal and distal to the anastomosis. Afterward, euthanasia was performed by cervical dislocation.



**Figure 1.** A short brief of the study on phenytoin.

## Anastomotic Bursting Pressure Measurement

A special mechanism was created to measure the burst pressure. One end of the intestinal segment, which was resected with a 2 cm border on the proximal and distal of the anastomosis line, without deteriorating the adhesions around the anastomosis, was tied with 3/0 silk and the other end was attached to the device. Methylene blue added isotonic was given at a constant rate of 3 mL/min and the anastomosis area was observed. The pressure at the point where methylene blue was seen outside the anastomosis was recorded as burst pressure.

## Histologic/Immunohistochemistry Studies

On the 9<sup>th</sup> post-operative day, immediately after measuring the burst pressure of the anastomosis line under anesthesia, the intestinal segment will be resected 2 cm proximal and distal to the anastomosis line. The removed material will be fixed in 10% formaldehyde solution. After the tissues are kept in fixation solution for 24 h, macroscopic examination will be performed. After the intestinal segment is opened horizontally by entering from the anti-mesenteric face, sampling will be performed to include the anastomosis line mucosa, proximal and distal intact tissue segment, and its neighborhood. The samples taken will be paraffin blocks after routine detection and follow-up with alcohol and xylene solutions. 3 µm thick sections from the prepared blocks will be taken on the slide. Sections will be histochemical stained with Hematoxylin and Eosin and Masson Trichrome.

Other sections to be taken immunohistochemically will be stained with fibroblast growth factor 2 (FGF2), vascular endothelial growth factor (VEGF), transforming growth factor-beta (TGF-β), and p53. In immunohistochemical procedures, hydrogen peroxide receptor blockade will be performed after all samples are washed with phosphate-buffered solution (PBS). The samples were, then, collected with primary antibody FGF2 (Monoclonal antibody BT LAB, Cat No: BT-MCA0614, Shanghai, China) and TGF-β1 (Monoclonal antibody BT LAB, Cat No: BT-MCA1649, Shanghai, China). It was incubated with VEGF (Monoclonal antibodies Fine Biotech Co., Cat No: Fnab09933, Wuhan, China) and anti-p53 (Monoclonal antibodies Fine Biotech Co., Cat No: Fnab0608, Wuhan, China). This was followed by washing in PBS and incubation with secondary antibody. After the preparations were stained with chromogen, they were counterstained with hematoxylin.

In the histochemical and immunohistochemical studies, the preparations to be obtained are blinded by the pathologist under the light microscope; anastomotic line epithelialization, inflammatory cell infiltration (macrophage, neutrophil, lymphocyte ratios), collagen deposition, fibroblast, and vascular proliferation parameters were evaluated histologically using a numerical scale (0, absent; 1+, sporadic focal present; 2+, mild present; 3+, diffuse present; and 4+, marked severe/confluent epithelium), which were graded and scored.

## Molecular Process

### RNA Isolation and cDNA Synthesis

RNA isolation from samples taken for molecular analysis was performed using Trizol Reagent kit. RNA was quantified and then visualized with RNA gel. cDNA synthesis was carried out using Thermo reaction buffer, oligo dT, ribolock inhibitor, dNTP, and reverse transcriptase components from RNAs in recommended amounts.<sup>[6-8]</sup> To check the operability of cDNAs, internal gene expression was examined. A 2% agarose gel was prepared for the visualization of DNA in the gel.

### Real-time PCR Analysis

Real-time PCR studies were performed using 5 µL of SYBR® Green PCR Master Mix, 1 µL of cDNA, 0.5 µL, and 3 µL of dH<sub>2</sub>O from a stock of 100 ng/µL forward and reverse primers in a final volume of 10 µL.<sup>[9-11]</sup> The sequence of the primers used for real-time PCR is indicated as below: TGF-βF: 5'GCT CAG TCT GTC TAC CTG CA-3' R: 5'-GGC GGG ATG GCA TCA AGG TA-3'; FGF2 F: 5'-ACT TCG CTT CCC GCA CTG C-3'R: 5'-CCA GTT GGT ATG TGG CAC TG-3', VEGF F:5'-CCCATGAAGT GGTGAAGTTC-3' and R: 5'-GAACAAGGCTCACAGTGAAC-3'; p-53 F: 5'-AGA CAT TTT CAT GCT TAT GG-3'R: 5'-ACC ATC AGA GCA ACG CTC AT-3'; GAPDH F:5'CTG GAG AAA CCT GCC AAG TAT G-3' R: 5'-GGT GGA AGA ATG GGA GTT GCT-3'. The results were evaluated according to the Livak method. Accordingly, each cDNA was run at least 3 times with the relevant gene and internal control rat GAPDH primers.

## Statistical Analysis

GraphPad Prism 8 software was used for statistical analysis. The descriptive statistical methods (Mean, Standard Deviation, Median, Frequency, Ratio, Minimum, Maximum) were carried out. All results are shown as mean±standard deviation (SD). One-way ANOVA test was used to compare all groups. P values 0.05 were considered statistically significant.

## RESULTS

### Anastomotic Bursting Pressure

Anastomotic bursting pressure indicates how much the repaired tissue resists breaking under tension and consequently may represent partly the quality of repaired tissue. The effects of phenytoin on anastomotic bursting pressure analysis measured on the 9<sup>th</sup> post-operative day in incision model are shown in Table 1. There are statistically significant increase differences in anastomotic bursting pressure values between control and phenytoin application groups (Group B: IAP, Group C: OAP, and Group D: RAP). The most effective application of phenytoin was found to be significantly higher in RAP than other groups (p<0.05).

### Histopathological Analysis

The effect of different treatment approaches, IAP, OAP, and

**Table 1.** Anastomotic bursting pressure analysis in 9<sup>th</sup> day after operation

Groups	N	Mean±SD	Min–Max (Median)	p
Group A Control	10	187.5±31.02	14–230 (186)	0.001**
Group B Intraperitoneal Phenytoin Group	10	288.8±17.09	270–325 (283)	
Group C Oral Phenytoin Group	10	284±4.57	277–292 (284)	
Group D Rectal Phenytoin Group	10	301.7±6.91	292–310 (302)	

Statistical analysis were indicated as \*p<0.01, \*\*p<0.005, \*\*\*p<0.001, \*\*\*\*p<0.0001. n.s.: Not significant; SD: Standard deviation.

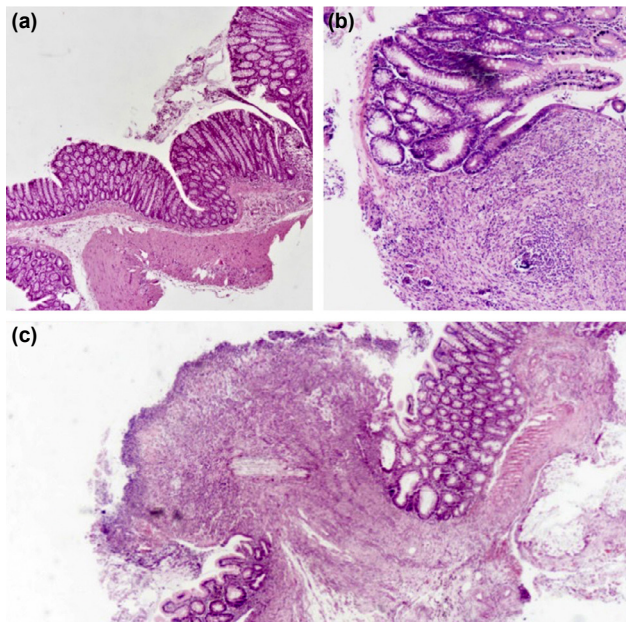
**Table 2.** Histological data from the colonic anastomoses

Histological parameters	Control (1 <sup>st</sup> day)	Control (9 <sup>th</sup> day 1)	IAP (9 <sup>th</sup> day 2)	OAP (9 <sup>th</sup> day 2)	RAP (9 <sup>th</sup> day 2)
Inflammatory cell infiltrate	1.2±0.42	3.3±0.67***	2.5±0.53*	2.1±0.57**	2.6±0.84 n.s.
Fibroblast	0.8±0.11	2.8±0.63****	2.5±0.53 n.s.	3.2±0.42 n.s.	2.8±0.42 n.s.
Collagen deposition	1.27±0.5	2.2±0.42****	2.4±0.52 n.s.	3.1±0.57**	2.7±0.67 n.s.
Neovascularization	0.72±0.28	2.2±0.42****	2.6±0.52*	2.3±0.82 n.s.	2.1±0.32 n.s.
Re-epithelialization	3.9±0.5	2.2±0.79****	2.8±1.14 n.s.	2.9±1.2 n.s.	3.1±0.74 n.s.

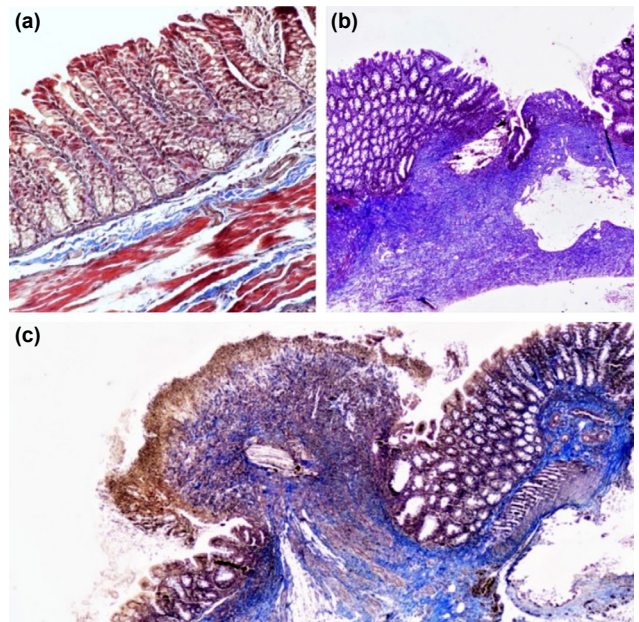
Statistical analysis were indicated as \*p<0.01, \*\*p<0.005, \*\*\*p<0.001, \*\*\*\*p<0.0001 and n.s. not significant. 1 represent the statistical analysis between 1<sup>st</sup> day control group and 9<sup>th</sup> day control group and 2 is the statistical analysis between 9<sup>th</sup> day control group and 9<sup>th</sup> day treatment group.

RAP, on the wound healing of anastomosis was investigated by histological examinations, namely, inflammatory cell infiltrate, fibroblast, collagen deposition, fibroblast, neovascularization, and epithelialization (Figs. 2 and 3). Histological scoring data from the colonic anastomoses are shown in Table 2.

As shown in Table 2, there are considerable differences in histopathological results, between 1<sup>st</sup> day and 9<sup>th</sup> day of post-operative day. All changes in histopathological features were statistically significant (p<0.00). Re-epithelialization scores and fibroblast activities of IAP, OAP, and RAP groups were



**Figure 2.** (a) In the area of the wound anastomosis line, epithelialization is fully developed and low inflammation is observed Hematoxylin and Eosin (H&E, ×40), (b) single-layer epithelium with epithelialization started on the granulation tissue in the anastomosis line, significant inflammation is observed (H&E ×100), and (c) there is significant inflammation and granulation tissue in the wound anastomosis line but no epithelialization yet (H&E ×40).



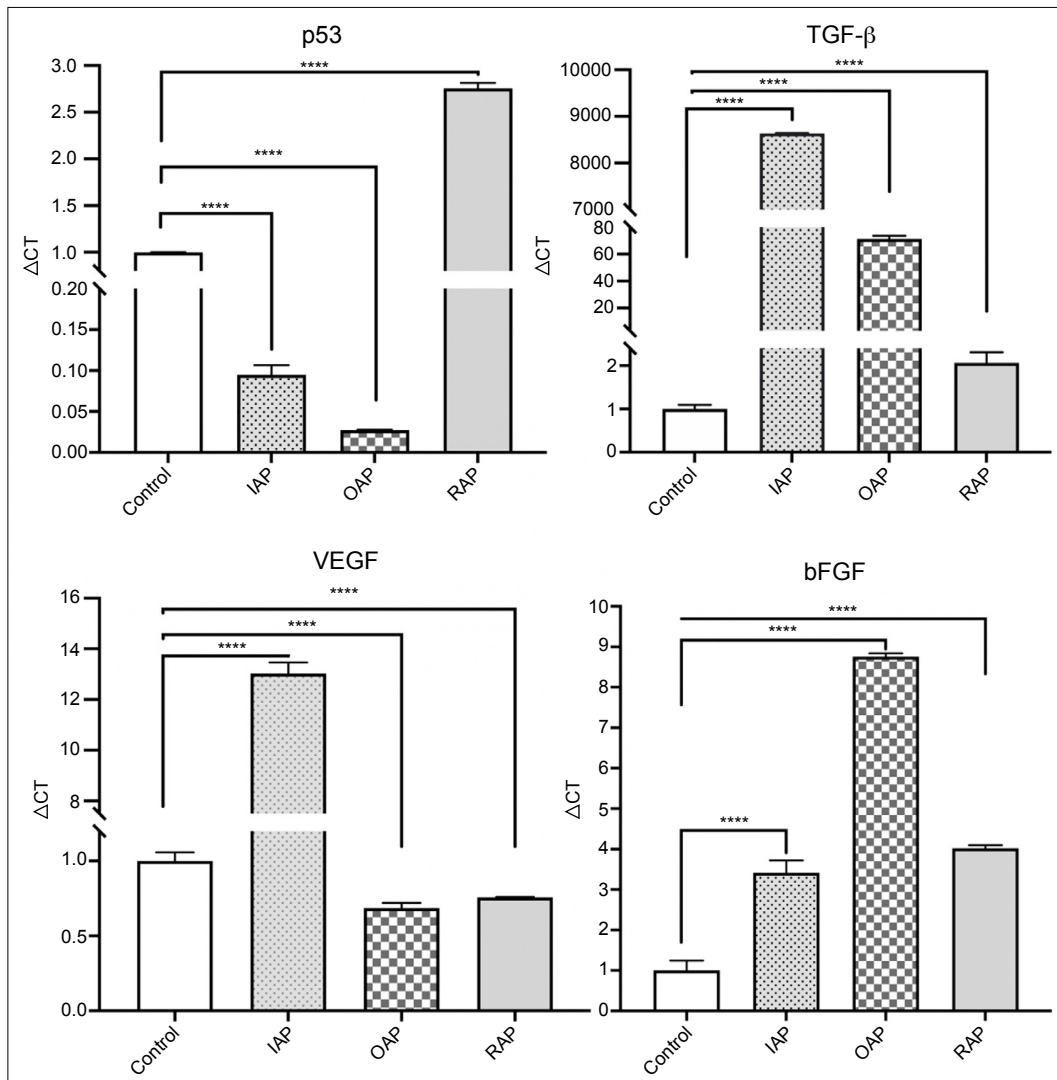
**Figure 3.** (a) Wall fibrous tissue Masson Trichrome (MTC, ×200) in the normal bowel segment, (b) epithelialization has started on the granulation tissue in the wound anastomosis line and increased collagen tissue is observed around it (MTC ×40), and (c) in addition to significant inflammation in the anastomosis line, epithelialization has not started and low collagen tissue is observed (MTC ×40).

not significant with the control group of 9<sup>th</sup> day, as shown in Table 2. In terms of the neovascularization score, there was an insignificant difference between control and OAP and RAP groups, whereas neovascularization score of IAP group increased in statistically important manner ( $p < 0.01$ ). When the fibroblast scores of the intestinal tissue on the 1<sup>st</sup> and 9<sup>th</sup> days were compared, fibroblast values on the 9<sup>th</sup> day were found to be significantly higher than the 1<sup>st</sup> day of operation ( $p < 0.0001$ ). However, in the phenytoin-treated groups, there is no significant change in the fibroblast score compared to the score of the 9<sup>th</sup> of post-operative day. The number of inflammatory cell infiltrate, including neutrophils, macrophages, and fibroblasts cells in the experimental groups, IAP, and OAP, was significantly lower than the control group,  $p < 0.01$  and  $p < 0.00$ , respectively. There is no statistically significant reduction observed in the comparison of RAP approach to the control group. In addition, in the phenytoin-treated group, collagen fiber organization was significantly higher than in the control group for OAP ( $p < 0.005$ ). However, there is

no statistically important increase in IAP and RAP treatments (n.s.) (Table 2).

### Molecular Studies

Considering the observed changes on histological data in intestinal tissue after phenytoin treatment, we next analyzed the transcript levels of tissue renewal and angiogenesis parameters. The effect of phenytoin on the wound healing of anastomosis healing was determined by assessment of the mRNA expression of VEGF, FGF2, TGF- $\beta$ , and p53 gene in phenytoin and control groups. Changes in the gene expressions were investigated on day 9 of wounding in the rats by real-time PCR. The expression of a target gene was normalized by human beta microglobulin housekeeping gene as normalizing gene. Expression of VEGF gene was significantly increased in IAP phenytoin groups compared with 9<sup>th</sup> control group in rats ( $p < 0.001^{***}$ ) (Fig. 4). Whereas, the expression of VEGF in IAP and OAP phenytoin groups was statistically decreased compared to 9<sup>th</sup> control tissue (Fig. 4).



**Figure 4.** The mRNA expression p53, VEGF, FGF2, and TGF- $\beta$  by real-time PCR in colon anastomoses of control and phenytoin treated rats. Means $\pm$ SD are shown. \*Represent  $p < 0.01$ , \*\* $p < 0.001$ , and \*\*\* $p < 0.0001$ .

To assess the apoptotic cell death, p53 expression level that is the main transcription factor regulating apoptotic process was determined from the 9<sup>th</sup> of post-operative day and different phenytoin treatment approaches. In addition, p53 was found to suppress VEGF expression indicating its expression with VEGF inhibition.<sup>[12]</sup> p53 mRNA level was increased in RAP treatment, but decreased in OAP and IAP (Fig. 4).

TGF-β and FGF2 are other indicators for tissue renewal process since TGF-β and FGF2 were known as main regulators in matrix remodeling. TGF-β mRNA expression was increased in IAP and RAP treatment but, decreased in OAP. In addition, all rats under phenytoin treatment increased transcript levels of FGF2s (Fig. 4).

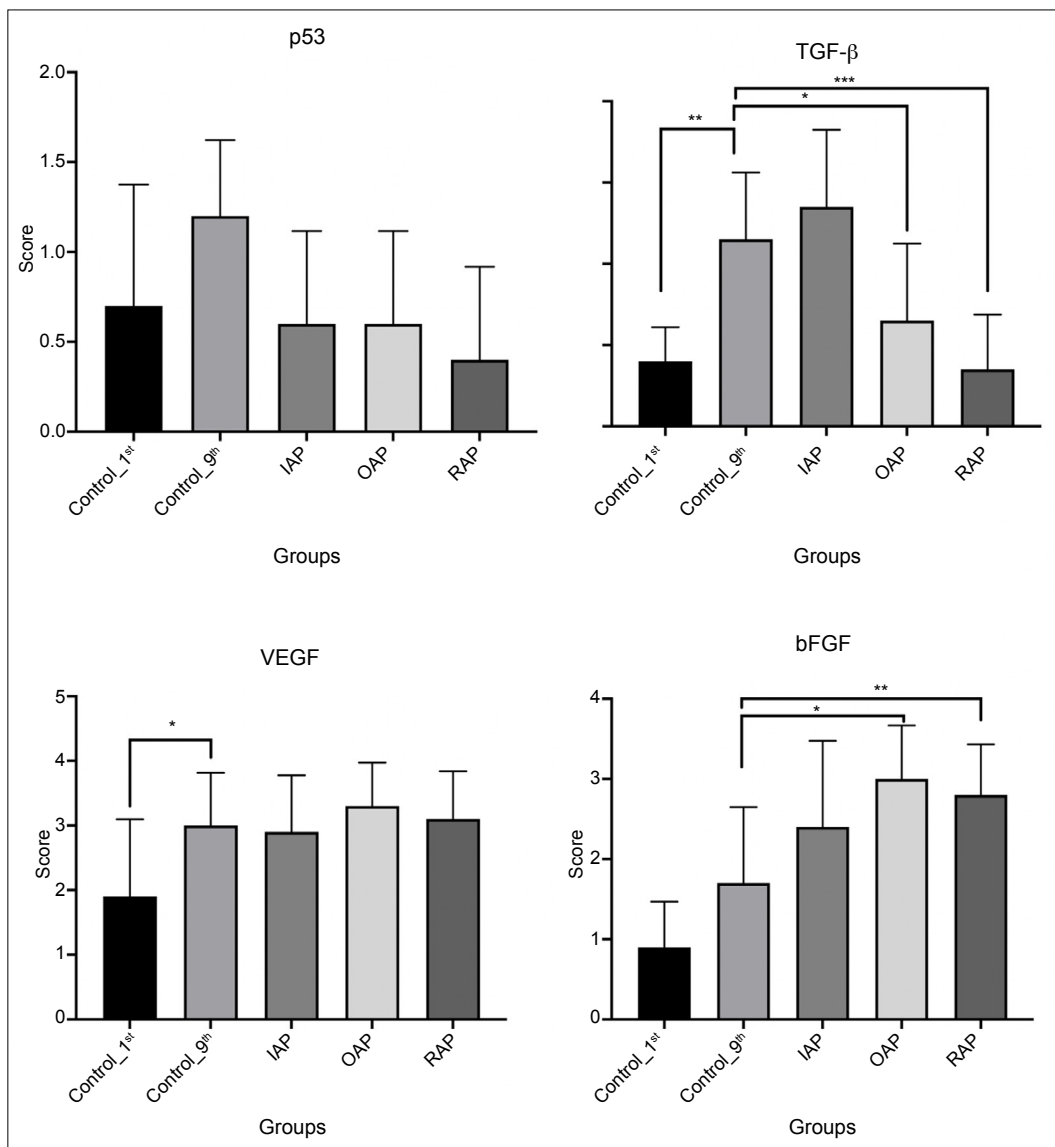
### Immunohistochemistry

To confirm the protein expression of some markers in in-

testinal tissue, immunohistochemistry was performed. When the value of FGF2 value in the intestinal tissue on the 1<sup>st</sup> day was compared with the value in the intestinal anastomosis on the 9<sup>th</sup> day, the FGF2 value on the 9<sup>th</sup> day was found to be statistically higher. On the 9<sup>th</sup> day, a significantly higher FGF2 protein expression in the intestinal anastomosis was found in the OAP and RAP phenytoin group compared to the control group, p=0.001 and p<0.05, respectively (Fig. 5).

VEGF levels in the intestinal anastomosis were compared on the 1<sup>st</sup> and 9<sup>th</sup> days and were found to be significantly higher on the 9<sup>th</sup> day. However, there is no significant increase in VEGF protein expression level in all phenytoin groups (Fig. 5).

TGF-β protein expression in the intestinal anastomosis in the 9<sup>th</sup> day was increased in the 1<sup>st</sup> day control group. There is also increase in phenytoin IAP treatment, but this increase



**Figure 5.** The protein expression p53, VEGF, FGF2, and TGF-β by immunohistochemistry in colon anastomoses of control and phenytoin treated rats. Means±SD are shown. \*Represent p<0.01, \*\*p<0.001, and \*\*\*p<0.0001.

was not statistically important. In contrast, TGF- $\beta$  protein expression in phenytoin with RAP and OAP treatment decreased compared to the 9<sup>th</sup> day of control group (Fig. 5).

There is no statistical significant change in p53 protein expression in the intestinal anastomosis of all phenytoin treated groups compared to 9<sup>th</sup> day of control group.

## DISCUSSION

Wound healing that occurs after tissue damage consists of hemostasis, inflammation, proliferation, repair, and remodeling stages. Many molecules have been studied in wound healing models over the years. In this process, it is known that phenytoin acts through mechanisms such as increasing in fibroblast proliferation, inhibition of collagenase activity, support of collagen distribution, formation of granulation tissue, and increasing in growth factor receptors.<sup>[4,13]</sup>

It is known that inflammatory cells accumulate in the damaged area from the 1<sup>st</sup> day of wound healing. With the formation of epithelialization, it causes a decrease in the inflammatory cell population, especially neutrophils.<sup>[14]</sup> Abdou et al.<sup>[13]</sup> were indicated in a study of using local phenytoin in vitiligo patients, polymorphonuclear, and eosinophil cells which were decreased in skin biopsies. In our study, inflammatory cell infiltration was increased in the intestinal anastomosis region compared to the 1<sup>st</sup> day in all groups. However, compared to cell infiltrate of the 9<sup>th</sup> day control group, there is statistically significant decrease of inflammatory cell infiltrate in phenytoin IAP and OAP groups. The fact that phenytoin causes a decrease in inflammatory cells in the damaged tissue was compatible with the literature.

Fibroblasts are known to be very important in the process to complete epithelialization of damaged tissue by secreting growth factors, cytokines, collagens, and extracellular matrix components.<sup>[15]</sup> In a study by Tokgöz et al.<sup>[15]</sup> investigating the effect of phenytoin on the vocal cord in rats, it was shown that phenytoin significantly increased fibroblast density in histological examination. Similarly, Turan et al.<sup>[6]</sup> were investigated an increase of fibroblasts in wound healing area. In consistent with the literature, our study reports that fibroblast scores in the intestinal anastomosis increased on the 9<sup>th</sup> day when compared with the 1<sup>st</sup> day in all groups. However, in the phenytoin-treated groups, there is no significant change in the fibroblast score compared to the score of the 9<sup>th</sup> of post-operative day.

In terms of neovascularization, in our study, there was a significant increase in neovascularization scores between the 1<sup>st</sup> day and the 9<sup>th</sup> day in all groups in the neovascularization evaluation of intestinal anastomosis. On the 9<sup>th</sup> day of intestinal anastomoses, the neovascularization value of the IAP phenytoin group was found to be significantly higher than control group (\* $p < 0.01$ ). Other treatment strategies show no statistically significant difference. Shakeri et al.<sup>[4]</sup> investigated

the diabetic foot wounds in dresses with powdered phenytoin tablet and paste made using saline. They determined that neovascularization increased in the phenytoin group. Similar results were also shown in the wound healing model of Habibipour et al.<sup>[17]</sup> on rats.

It has been reported that the effect of phenytoin on collagen is by decreasing the collagenase activity and supporting the distribution of collagen.<sup>[4,13]</sup> In the study of Tokgöz et al.<sup>[15]</sup> on the vocal cord, there was an increase in collagen as well as in fibroblasts. In an *in vivo* wound healing studies, it was observed that there was a significant increase in collagen accumulation in the phenytoin group by Turan et al. In our study, there is an increase in collagen deposition between 1<sup>st</sup> and 9<sup>th</sup> day control groups. Although the results are compatible with the literature, there are differences in the way of application. On the 9<sup>th</sup> day of intestinal anastomosis, collagen scores were found to be significantly higher in the OAP and RAP phenytoin groups compared to the control group.

Epithelialization is defined as the process that takes place in the proliferative phase of wound healing and continues the progression of the epithelium over the granulation tissue. It was shown that the epithelialization time was shortened in application of topical phenytoin on diabetic foot wounds. In addition, similarly increased granulation was investigated by Kumar et al.<sup>[18,19]</sup> In our study, there is a decrease in re-epithelialization score between 1<sup>st</sup> day and 9<sup>th</sup> of control group. No statistical difference was found in other routes of administration on the 9<sup>th</sup> day of intestinal anastomosis.

It is known that phenytoin causes gingival hyperplasia during its use as an antiepileptic drug. In the review of Corrêa et al.<sup>[20]</sup> due to this side effect, it was found that FGF2 was high in hyperplastic gingiva. Moreover, the increase of FGF2 expression was shown by Turan et al. In our study, FGF2 expression was evaluated in mRNA and protein level. In consistent with mRNA and protein expression, higher FGF2 expression levels were determined from IAP, OAP, and RAP use of phenytoin levels compared to the control group.

Şimşek et al.<sup>[21]</sup> reported that VEGF protein was highly expressed in phenytoin group in nasal mucosa. In our study, VEGF expression at mRNA level increased with IAP phenytoin use, whereas no change occurred for OAP and RAP use. Similarly, high VEGF expression was also shown by PCR in skin wound.<sup>[22]</sup> The protein level of VEGF was not significant important.

Although, p53 which is a member of tumor suppressor gene family, which was not studied within wound healing process, it was found to suppress VEGF expression.<sup>[23]</sup> In wound healing process, it was known that VEGF suppression has negative effects. In our study, in the 9<sup>th</sup> of intestinal anastomosis, p53 mRNA level decreases in the IAP and OAP phenytoin use but increases in the RAP phenytoin use, although there is no statistically significant change detected from TGF- $\beta$  protein ex-

pression level. Consequently, the decrease of p53 level will correlate with the increase of VEGF level for IAP phenytoin use, indicating this route might be favorable way for vascularity.

Wound healing resulted from both keratinocytes and fibroblasts. It has been shown that the contraction of collagen and differentiation of myofibroblasts plays an important role in the formation of granulation tissue.<sup>[24]</sup> TGF- $\beta$  expression levels were found to be high on the 7<sup>th</sup> day in the phenytoin group, but decreased on the 21<sup>st</sup> day by Savari et al.<sup>[22]</sup> Similarly, our study indicated that there is some variation of TGF- $\beta$  expression level. mRNA of TGF- $\beta$  expression increased with all route of phenytoin applications despite the protein of TGF- $\beta$  shows variable effects.

In our study, bursting pressures were found to be significantly higher in all phenytoin-administered groups compared to the control group. When the study groups were compared among themselves, bursting pressures after rectal administration were found to be higher than the oral and intraperitoneal groups. In another study, oral and rectal administration of phenytoin was compared with the control group, and burst pressures were found to be significantly higher in the phenytoin administered groups.<sup>[25]</sup>

## Conclusion

In our study, it was aimed to increase the safety of surgical process of colorectal anastomosis. For this purpose, considering the previously observed positive effects of phenytoin on wound healing, detail analyses were carried out at both histological and molecular levels. As a result, it has been shown that application of phenytoin has positive effects on colorectal anastomoses and wound healing.

**Ethics Committee Approval:** This study was approved by the Balikesir University Animal Experiments Local Ethics Committee (Date: 29.04.2021, Decision No: 2021/4-7).

**Peer-review:** Internally peer-reviewed.

**Authorship Contributions:** Concept: A.D., F.Ç., N.H., E.T., F.K., E.A., M.B., A.G.Ş., H.Y., U.M., H.P.; Design: A.D., F.Ç., N.H., E.T., F.K., E.A., M.B., A.G.Ş., H.Y., U.M., H.P.; Supervision: A.D., F.Ç., N.H., E.T., F.K., E.A., M.B., A.G.Ş., H.Y., U.M., H.P.; Fundings: A.D., F.Ç., N.H., E.T., F.K., E.A., M.B., A.G.Ş., H.Y., U.M., H.P.; Materials: A.D., F.Ç., N.H., E.T., F.K., E.A., M.B., A.G.Ş., H.Y., U.M., H.P.; Data: A.D., F.Ç., N.H., E.T., F.K., E.A., M.B., A.G.Ş., H.Y., U.M., H.P.; Analysis: A.D., F.Ç., N.H., E.T., F.K., E.A., M.B., A.G.Ş., H.Y., U.M., H.P.; Literature search: A.D., F.Ç., N.H., E.T., F.K., E.A., M.B., A.G.Ş., H.Y., U.M., H.P.; Writing: A.D., F.Ç., N.H., E.T., F.K., E.A., M.B., A.G.Ş., H.Y., U.M., H.P.; Critical revision: A.D., F.Ç., N.H., E.T., F.K., E.A., M.B., A.G.Ş., H.Y., U.M., H.P.

**Conflict of Interest:** None declared.

**Financial Disclosure:** The study was financially supported by Balikesir University Research Project (2020/067).

## REFERENCES

- Phillips BR. Reducing gastrointestinal anastomotic leak rates: Review of challenges and solutions. *Open Access Surg* 2016;9:5–14. [[CrossRef](#)]
- McDermott FD, Heeney A, Kelly ME, Steele RJ, Carlson GL, Winter DC. Systematic review of preoperative, intraoperative and postoperative risk factors for colorectal anastomotic leaks. *Br J Surg* 2015;102:462–79.
- Thomas MS, Margolin DA. Management of colorectal anastomotic leak. *Clin Colon Rectal Surg* 2016;29:138–44. [[CrossRef](#)]
- Shakeri E, Tebyanian H, Karami A, Babavalian H, Tahmasbi MH. Effect of topical phenytoin on wound healing. *Trauma Mon* 2017;22:5. [[CrossRef](#)]
- Ramalingam A, Saravana K, Sekar A. A study of topical phenytoin sodium in diabetic foot ulcer healing. *Ann Int Med Dent Res* 2017;3:43–8.
- Tokay E, Kockar F. Identification of intracellular pathways through which TGF- $\beta$ 1 upregulates URG4/URGCP gene expression in hepatoma cells. *Life Sci* 2016;144:121–8. [[CrossRef](#)]
- Yildirim H, Karaman M, Kockar F. The role of hypoxia response element in TGF $\beta$ -induced carbonic anhydrase IX expression in Hep3B human hepatoma cells. *Arch Biol Sci* 2017;69:593–601. [[CrossRef](#)]
- Alper M, Kockar F. IL-6 upregulates a disintegrin and metalloproteinase with thrombospondin motifs 2 (ADAMTS-2) in human osteosarcoma cells mediated by JNK pathway. *Mol Cell Biochem* 2014;393:165–75.
- Tokay E, Kockar F. SP1 is a transcriptional regulator of URG-4/URGCP gene in hepatocytes. *Mol Cell Biochem* 2016b;423:75–83.
- Hacıoğlu N, Güngör T, Tokay E, Önder FC, Ay M, Köçkar F. Synthesis and biological evaluation of 2, 4, 6-trinitroaniline derivatives as potent antitumor agents. *Monatsh Chem* 2020;151:1629–41. [[CrossRef](#)]
- Aydemir AT, Alper M, Kockar F. SP1-mediated downregulation of ADAMTS3 gene expression in osteosarcoma models. *Gene* 2018;659:1–10. [[CrossRef](#)]
- Morton LM, Phillips TJ. Wound healing and treating wounds: Differential diagnosis and evaluation of chronic wounds. *J Am Acad Dermatol* 2016;74:589–605. [[CrossRef](#)]
- Abdou AG, Abdelwahed Gaber M, El-Naidany NF, Elnagar A. Evaluation of the effect and mechanism of action of local phenytoin in treatment of vitiligo. *J Immunoassay Immunochem* 2017;38:523–37. [[CrossRef](#)]
- Maddaluno L, Urwyler C, Werner S. Fibroblast growth factors: Key players in regeneration and tissue repair. *Development* 2017;144:4047–60.
- Tokgöz SA, Saka C, Akin I, Köybaşıoğlu F, Kılıçslan S, Çalıřkan M, et al. Effects of phenytoin injection on vocal cord healing after mechanical trauma: An experimental study. *Turk J Med Sci* 2019;49:1577–81.
- Turan M, Saraydın SU, Bulut HE, Elagöz S, Cetinkaya O, Karadayı K, et al. Do vascular endothelial growth factor and basic fibroblast growth factor promote phenytoin's wound healing effect in rat? An immunohistochemical and histopathologic study. *Dermatol Surg* 2014;30:1303–9.
- Habibipour S, Oswald TM, Zhang F, Joshi P, Zhou XC, Dorsett-Martin W, et al. Effect of sodium diphenylhydantoin on skin wound healing in rats. *Plast Reconstr Surg* 2013;112:1620–7. [[CrossRef](#)]
- Hajong R, Naku N, Hajong D, Anand M, Singh KL, Majumdar N. Effect of topical phenytoin on wound healing. *Group* 2016;1:17–36. [[CrossRef](#)]
- Kumar CS, Vasudeva N, Rao DV, Naidu CR. Outcomes of topical phenytoin in the management of traumatic wounds. *J Clin Orthop Trauma* 2021;13:116–21. [[CrossRef](#)]
- Corrêa JD, Queiroz-Junior CM, Costa JE, Teixeira AL, Silva TA. Phenytoin-induced gingival overgrowth: A review of the molecular, immune, and inflammatory features. *ISRN Dent* 2011;2011:497850. [[CrossRef](#)]
- Şimşek G, Ciftci O, Karadag N, Karatas E, Kizilay A. Effects of topical phenytoin on nasal wound healing after mechanical trauma: An experimental study. *Laryngoscope* 2014;124:449–54. [[CrossRef](#)]
- Savari R, Shafiei M, Galehdari H, Kesmati M. Expression of VEGF and TGF- $\beta$  genes in skin wound healing process induced using phenytoin in male rats. *Jundishapur J Health Sci* 2019;11:e86041. [[CrossRef](#)]



23. Meckmongkol TT, Harmon R, McKeown-Longo P, Van De Water L. The fibronectin synergy site modulates TGF- $\beta$ -dependent fibroblast contraction. *Biochem Biophys Res Commun* 2007;360:709–14. [CrossRef]
24. Qin G, Kishore R, Dolan CM, Silver M, Wecker A, Luedemann CN, et al. Cell cycle regulator E2F1 modulates angiogenesis via p53-dependent transcriptional control of VEGF. *Proc Natl Acad Sci U S A* 2006;103:11015–20. [CrossRef]
25. Turan M, Saraydin SU, Canbay E, Karadayi K, Bulur E, Cetinkaya Ö, et al. Positive effects of phenytoin on experimental colonic anastomoses. *Int J Colorectal Dis* 2014;19:250–7. [CrossRef]

## DENEYSEL ÇALIŞMA - ÖZ

### Şıçanlarda ameliyat sonrası intraperitoneal, oral ve rektal fenitoin uygulamasının kolorektal anastomoz üzerine etkilerinin araştırılması

Dr. Ali Duran,<sup>1</sup> Dr. Ferhat Çay,<sup>1</sup> Dr. Nelin Hacıoğlu,<sup>2</sup> Dr. Esra Tokay,<sup>2</sup> Dr. Feray Köçkar,<sup>2</sup> Dr. Eren Altun,<sup>3</sup> Dr. Murat Başbuğ,<sup>1</sup> Dr. Azad Gazi Şahin,<sup>1</sup> Dr. Hasan Yaşar,<sup>1</sup> Dr. Uğur Mengeneçci,<sup>1</sup> Dr. Hüseyin Pülüt<sup>4</sup>

<sup>1</sup>Balıkesir Üniversitesi Tıp Fakültesi, Cerrahi Anabilim Dalı, Balıkesir

<sup>2</sup>Balıkesir Üniversitesi Fen-Edebiyat Fakültesi, Moleküler Biyoloji ve Genetik Bölümü, Balıkesir

<sup>3</sup>Sağlık Bilimleri Üniversitesi, Bağıcılar Eğitim ve Araştırma Hastanesi, Patoloji Anabilim Dalı, İstanbul

<sup>4</sup>Mersin Şehir Hastanesi, Genel Cerrahi Kliniği, Mersin

**AMAÇ:** Anastomoz kaçığı kolon anastomozlarından sonra en korkulan komplikasyondur. Bu çalışmanın amacı, farklı uygulama yollarıyla uygulanan fenitoinin kolorektal anastomozların iyileşme sürecine etkisini belirlemektir.

**GEREÇ VE YÖNTEM:** Wistar Albino şıçanlar, İntraperitoneal Fenitoin Grubu (İAP), Oral Fenitoin Grubu (OAP), Rektal Fenitoin Grubu (RAP) ve kontrol gruplarına ayrıldı. Fenitoinin VEGF, TGF- $\beta$ , FGF2 ve p53 genlerinin ekspresyonu üzerindeki moleküler etkisi mRNA ve protein düzeyinde değerlendirildi. Fenitoinin anastomoz patlama basıncı analizi üzerindeki etkilerinin yanı sıra patohistolojik incelemeler de ölçülmüştür.

**BULGULAR:** Kontrol ve uygulama grupları arasında anastomoz patlama basıncı değerlerinde istatistiksel olarak anlamlı artış vardır. Enflamatuvar hücre infiltrasyonu tüm gruplarda kontrole göre bağırsak anastomoz bölgesinde artmıştır. Kollajen skorları OAP ve RAP gruplarında kontrol grubuna göre anlamlı derecede yüksek bulundu. TGF- $\beta$ 'nin mRNA'sı ve FGF2 ekspresyonu, fenitoin uygulamalarının tüm yollarında artmıştır.

**TARTIŞMA:** Üç farklı uygulama yolu, patlama basıncında önemli bir artış göstermektedir. FGF2, TGF- $\beta$ , p53 ve VEGF genlerinin ekspresyon sonuçları ile ilgili olarak, çoğu uygulama yolunda mRNA ve protein seviyesinde FGF2 ve TGF- $\beta$ 'de önemli bir artış vardır.

**Anahtar sözcükler:** Cerrahi; epitelizasyon; fenitoin; kolorektal anastomoz; neovaskülarizasyon.

Ulus Travma Acil Cerrahi Derg 2022;28(9):1214-1222 doi: 10.14744/tjtes.2022.03704