

Journal of the Hellenic Veterinary Medical Society

Vol 73, No 2 (2022)



Intraocular Pressure Measured by Rebound Tonometry in Seven Raptor Species

Muhammed Kaan YÖNEZ, M Erol, H Erol, G Atalan, Z Doğan, M Kibar

doi: [10.12681/jhvms.21914](https://doi.org/10.12681/jhvms.21914)

Copyright © 2022, Muhammed Kaan YÖNEZ



This work is licensed under a [Creative Commons Attribution-NonCommercial 4.0](https://creativecommons.org/licenses/by-nc/4.0/).

To cite this article:

YÖNEZ, M. K., Erol, M., Erol, H., Atalan, G., Doğan, Z., & Kibar, M. (2022). Intraocular Pressure Measured by Rebound Tonometry in Seven Raptor Species. *Journal of the Hellenic Veterinary Medical Society*, 73(2), 3929–3934. <https://doi.org/10.12681/jhvms.21914>

Intraocular Pressure Measured by Rebound Tonometry in Seven Raptor Species

M. K. Yöñez¹, M. Erol², H. Erol¹, G. Atalan¹, Z. Doğan³, M. Kibar⁴

¹Department of Surgery, Faculty of Veterinary Medicine, Erciyes University, Kayseri, Turkey

²Department of Surgery, Faculty of Veterinary Medicine, University of Balıkesir, Kayseri, Turkey

³Veterinary clinic of Petiatri, İstanbul, Turkey

⁴Junior technical college of Artvin, University of Artvin Çoruh, Artvin, Turkey

ABSTRACT: The purpose of this study was to investigate the applicability of Rebound tonometer for the intraocular pressure measurement and to determine the correlation between intraocular pressure reference values and body weight in different raptor species. In the present study, intraocular pressure of 66 Long-legged buzzard (132 eyes), 20 Eurasian sparrowhawk (40 eyes), 13 Eurasian eagle-owl (26 eyes), 6 Golden eagles (12 eyes), 6 Common kestrels (12 eyes), 4 Peregrine falcon (8 eyes), 2 Griffon vulture (4 eyes), which referred to Erciyes University, Faculty of Veterinary Medicine, Department of Surgery Clinic were evaluated. In the ophthalmologic examination there was no lesion detected related to eyes. The mean body weight raptors was 1.10±0.23 kg in Long-legged buzzard, 0.23±0.06 kg in Eurasian sparrow hawk, 0.27±0.10 in Eurasian eagle-owl, 3.30±0.80 kg in Golden eagles, 0.18±0.04 kg in Common kestrels, 0.64±0.28 kg in Peregrine falcon and 2.28±0.43 kg in Griffon vulture. Rebound tonometer was used for measurement of intraocular pressure. Mean intraocular pressure of right and left eyes were in Long-legged buzzard 25.87±0.62-26.61±0.71, Eurasian sparrow hawk 11.90±0.40-12.05±0.41, Eurasian eagle-owl 12.00±0.63-12.61±0.57, Golden eagles 29.00±2.89-30.33±2.87, Common kestrels 11.75±0.17-10.83±0.47, Peregrine falcon 14.75±1.10-14.25±0.85 and Griffon vulture 15.00±1.00-14.50±0.50. As a result of the study, Rebound tonometer is a reliable method for measuring intraocular pressure in small eyes and minimizes stress, well tolerated by raptors in intraocular pressure measurements. While there was a positive correlation detected between body weight and IOP values among the species, no correlation was observed between body weight and IOP values within the same species. The intraocular pressure values obtained in this study will help veterinary ophthalmologists and wild animal veterinarians to evaluate changes intraocular pressure in raptor and contribute to the literature.

Keywords: Intraocular pressure, Raptor, Rebound tonometer.

Corresponding Author:
Muhammed Kaan Yöñez, Department of Surgery, Faculty of Veterinary Medicine,
Erciyes University, Kayseri, Turkey
E-mail address: kaanyonez@gmail.com

Date of initial submission: 21-11-2019
Date of acceptance: 04-01-2022

INTRODUCTION

Eyesight is very important for social interaction in domestic birds. In raptors, it is necessary for flying, feeding, adaptation to the habitat, reproduction, and survival (Moore, 2017). Raptors have well developed, relatively large, frontally directed globes, which give them a sharp sight necessary for predation. The globes are situated in the orbit and surrounded by periorbital structures (Davidson, 1997; Seruca et al., 2012). Trauma to the globe or surrounding structure is the most common ocular diseases of raptors. The anatomy and location of eyes make them vulnerable to traumatic lesions (Seruca et al., 2012). Intraocular pressure (IOP) measurement is a part of the ophthalmic examination in animals and evaluated by tonometry (Barsotti et al., 2013; Reuter et al., 2011). TonoVet is a new rebound tonometry device for determining IOP. It is widely used in animals with different modes (d, h, p). TonoVet has a probe covered with electric coils which create a magnetic field that presses the probe against the cornea. Voltage changes are converted to an electrical signal when the probe contacts the cornea. These voltage changes are used to calculate the IOP (Reuter et al., 2010, Reuter et al., 2011). Congenital and developmental ocular diseases are rarely seen in raptors (Labelle et al., 2012). Ocular disorders are more common findings in free-living birds than in others (Moore et al., 2017). In wild birds, ocular trauma has been reported as a common cause of ocular morbidity (more than 30%) (Seruca et al., 2012; Holt and Layne., 2008; Ress and Guyer., 2004). Kuhn et al., (2013) found ocular lesions in 50% of the eyes examined, even among captive raptors that were originally deemed unreleasable due to injuries unrelated to the eyes. A complete ophthalmic examination should be performed on every free-range raptor submitted for clinical evaluation. The assessment of IOP is crucial for a complete ophthalmic examination (Reuter et al., 2011).

The aim of this study was to investigate the applicability of TonoVet for the IOP measurement and to determine the correlation between IOP reference values and body weight in different raptor species.

MATERIAL AND METHODS

Animals

A total of 117 raptors were included in this study. Sixty-six Long-legged buzzard (*Buteo rufinus*), 20 Eurasian sparrow hawk (*Accipiter nisus*), four Peregrine falcon (*Falco peregrinus*), six Golden eagles

(*Aquila chrysaetos*), 13 Eurasian eagle-owl (*Bubo bubo*), two Griffon vultures (*Gyps fulvus*), six Common kestrels (*Falco tinnunculus*) were referred to the Surgery Department of the Faculty of Veterinary Medicine at Erciyes University for general health status assessment between 2014 and 2017 (Figure 1). Raptors had been previously free-living and had been brought to our hospital for health control and treatment by the Ministry of Forestry. Only healthy animals were included in the study. During the study, all birds were kept at the hospitalization unit of the Department of Surgery Training, Research and Practice Hospital of the Faculty of Veterinary Medicine at Erciyes University. All species were examined, and clinical signs were recorded.

Ophthalmic examination and IOP measurement

Before ophthalmic examination and IOP measurement, the talons of all birds were wrapped in sticking plaster to avoid injury. The examination was carried out 10 minutes after transportation and all raptors were placed on the examination table to eliminate the stress effect after removal from the cage. The ophthalmic examination including palpebral and direct light reflexes was carried out before IOP measurement. Sedatives and topical anesthesia were not used. The birds were held by their bodies by an assistant during the IOP measurement. Right eyes and then left eyes were measured with the use of TonoVet (RBT, I care, Vet, Helsinki, Finland) with the birds in dorsal recumbency position. The TonoVet with the disposable probe was held horizontally and 4-5 mm from the central corneal surface.

The TonoVet software is preprogrammed for six measurements, but the result can be seen from the first to the last measurement. The displayed IOP was an averaged value of six consecutive central corneal touches. After this, the letters d (calibration table for dogs and cats), h (for horses), or P (for not defined in any species) would appear on the display, followed by the IOP reading. The calibration of the device was set to "P" mode. The IOP measurements were performed between 8am and 12pm to minimize diurnal variation. The mean values of repeating five measurements with TonoVet were recorded. All ocular examinations and tonometry measurements were performed by the same person (MKY).

Statistical analysis

Data were evaluated with the IBM SPSS Statistics 21.0 package program. Summary statistics were

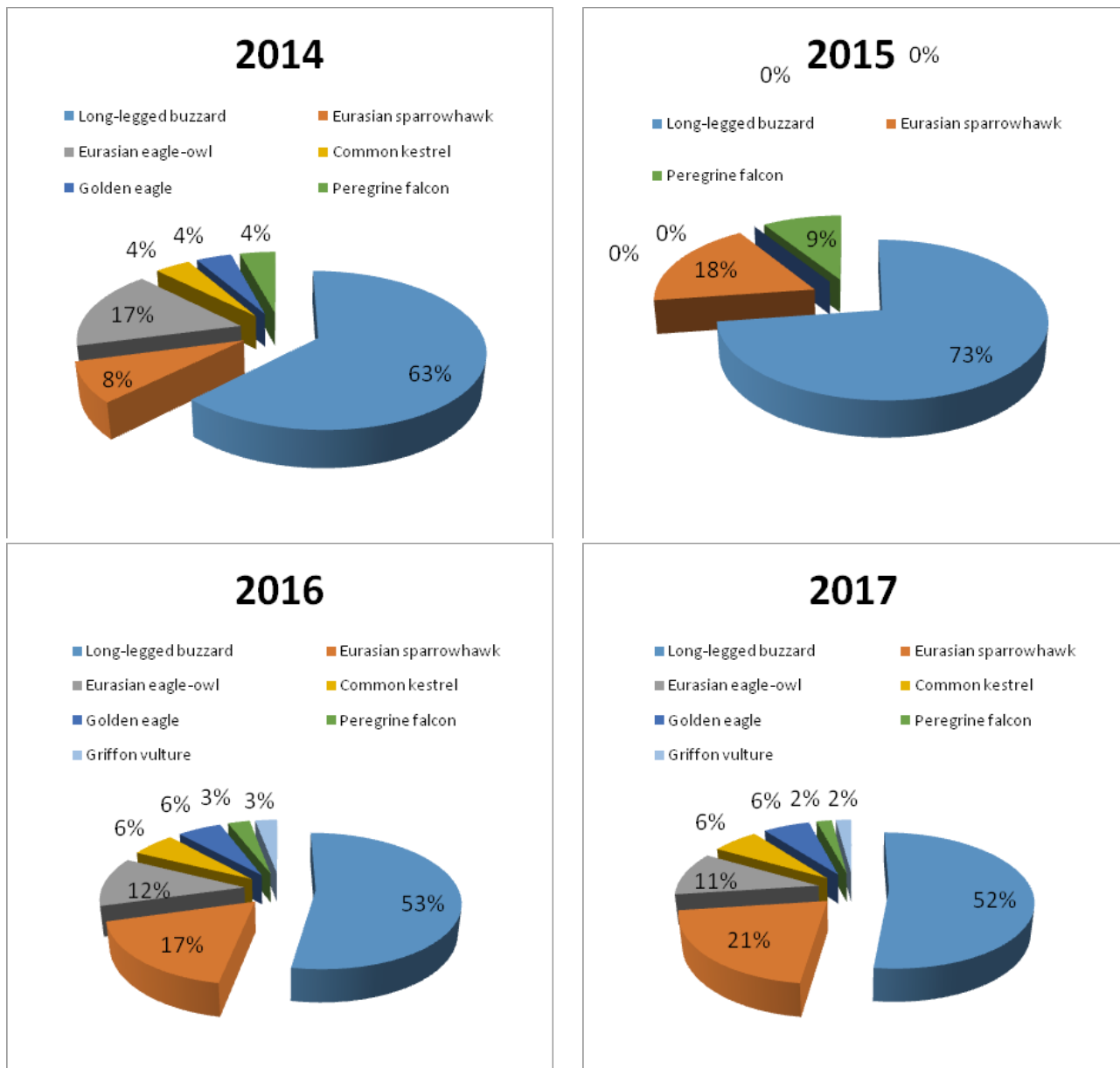


Figure 1. Distribution of raptors by years

given as a number of units (n), percentage (%), mean \pm standard error ($\bar{x} \pm SE$). The Shapiro-Wilk test was used for normality. One-Sample t-test was done for the evaluation of $\bar{x} \pm SE$. The Pearson correlation test was done for the correlation between body weight and the IOP. $P < 0.05$ and $P < 0.001$ values were considered statistically significant.

RESULTS

In total, 234 eyes were included in the study. The mean body weight and number of animals are pre-

sented in Table 1.

The left, right eyes and their mean IOP are presented in Table 2. The left eye IOP was higher than the right eye in Long-legged buzzards, Eurasian sparrow hawks, Eurasian eagle-owl, and Golden eagles. At the same time, the right eye IOP was higher than the left eye in Common kestrels, Peregrine falcons, and Griffon vulture. However, no statistically significant difference was found between right eye IOP and left eye IOP values in all evaluated raptors.

Table 1. Mean body weight of raptors

Species	n	kg
Long-legged buzzard (<i>Buteo rufinus</i>)	66	1.10±0.23
Eurasian sparrowhawk (<i>Accipiter nisus</i>)	20	0.23±0.06
Eurasian eagle-owl (<i>Bubo bubo</i>)	13	0.27±0.10
Golden eagle (<i>Aquila chrysaetos</i>)	6	3.30±0.80
Common kestrel (<i>Falco tinnunculus</i>)	6	0.18±0.04
Peregrine falcon (<i>Falco peregrinus</i>)	4	0.64±0.28
Griffon vulture (<i>Gyps fulvus</i>)	2	2.28±0.43

Table 2. Mean IOP values by raptor species

Species	n	Right eye Mean±SE	n	Left eye Mean±SE	p	n	Average Mean±SE
Long-legged buzzard (<i>Buteo rufinus</i>)	66	25.87±0.62	66	26.61±0.71	>0.05	132	26.24±0.47
Eurasian sparrow hawk (<i>Accipiter nisus</i>)	20	11.90±0.40	20	12.05±0.41	>0.05	40	11.97±0.28
Eurasian eagle-owl (<i>Bubo bubo</i>)	13	12.00±0.63	13	12.61±0.57	>0.05	26	12.30±0.42
Golden eagle (<i>Aquila chrysaetos</i>)	6	29.00±2.89	6	30.33±2.87	>0.05	12	29.66±1.95
Common kestrel (<i>Falco tinnunculus</i>)	6	11.75±0.17	6	10.83±0.47	>0.05	12	11.29±0.27
Peregrine falcon (<i>Falco peregrinus</i>)	4	14.75±1.10	4	14.25±0.85	>0.05	8	14.50±0.65
Griffon vulture (<i>Gyps fulvus</i>)	2	15.00±1.00	2	14.50±0.50	>0.05	4	14.75±0.47

DISCUSSION

Perfect visual function is essential for raptors to survive in the wild. The IOP measurement is an essential part of a detailed ophthalmic examination and should be conducted very carefully in raptors. The alterations of IOP give information about ophthalmic diseases such as glaucoma and uveitis. There are not enough studies and information about raptors' normal IOP value and ocular diseases (Moore et al., 2017; Reuter et al., 2011). The purpose of this study was to establish IOP values in different raptor species to determine the correlation between intraocular pressure reference values and body weight in different raptor species.

The TonoVet and applanation tonometry (Tonopen) are frequently used to measure IOP in animal. However, previous studies have reported that Tonopen causes stress and increase in systemic blood pressure due to pressure on the eyeball during the

measurement. In addition, IOP measurement time is 10 minutes due to the necessity of using topical anesthesia by using Tonopen (Dubicanac et al., 2018). On the contrary, TonoVet has advantages such as no need for local anesthesia, easy application and only 30 sec for conducting the measurement. These advantages minimize the stress and help to obtain reliable results in IOP measurements. In our study, we measured IOP in Common kestrel, Eurasian eagle-owl and Eurasian sparrow hawk species, which has small corneal diameters, with TonoVet. There was no difficulty encountered during measurement in these species. TonoVet was well tolerated and measurements were carried out practically. This condition showed that TonoVet could be practically used in small corneal diameter raptor species.

In recent study, Karimi et al., (2020) compared the IOP in 8 different domestic bird species. They found

that the difference between IOP measurements of the largest (4.93 ± 1.91 in African gray parrots) and the smallest bird species (5.90 ± 2.11 in Zebra Finch) was less than 1 mmHg. In another study on raptor, Reuter et al., (2011) found statistically important difference in IOP values between Accipitridae and Falconidae, Strigidae families. IOP values of Accipitridae family were higher than Falconidae and Strigidae families ($P .025$). In the study, 18 mmHg difference were found between IOP of largest species (29.66 ± 1.95 in Golden eagle) and the smallest species (11.29 ± 0.27 in Common kestrel). The differences in IOP values of raptor species were more prominent than domestic ones. In the present study, IOP values of Accipitridae family were higher than Falconidae and Strigidae families. Therefore, the obtained data supported the results of the Reuter et al.'s study. Difference between IOP values of raptor species may be derived from differences in corneal curvature and corneal thickness between species. But this situation requires more investigation.

In the present study, the lowest IOP value was measured in Common kestrels (11.29 ± 0.27) and the highest IOP value was measured in Golden eagles 29.66 ± 1.95 . Considering the body weight averages, the lowest in the Common kestrels (0.18 ± 0.04 kg) and the highest in the Golden eagles (3.30 ± 0.80 kg) were determined. In heavy weighted species (Golden eagle, Long-legged buzzard and Griffon vultures) higher IOP values 29.66 ± 1.95 , 26.24 ± 0.47 , 14.75 ± 0.47 were measured, respectively. In light weighted species (Eurasian sparrowhawk, Eurasian eagle-owl, Common kestrel and Peregrine falcon) IOP values 11.97 ± 0.28 , 12.30 ± 0.42 , 11.29 ± 0.27 , 14.50 ± 0.65 were measured, respectively. There was a positive correlation detected between body weight and IOP values among the species included in our study. However, Griffon vultures were heavier than Long-legged buzzard, IOP values of Griffon vultures were lower than Long-legged buzzard. In addition, when body weight and IOP alterations were evaluated in birds within the same species, it was found that body weight had no effect on IOP.

Reuter et al., (2011) measured the IOP by Rebound Tonometry in ten raptor species. In our study, there were only 3 same species with Reuter et al.'s study (Common kestrel, Peregrine falcon, Eurasian sparrow hawk). They found 9.8 ± 2.5 mmHg in the left eyes of Common kestrels, 12.7 ± 5.8 mmHg in Peregrine falcons and 15.5 ± 2.5 mmHg in Eurasian sparrowhawks. However, Reuter et al., (2011) grouped the raptors as

nestling, juvenile and adult. They reported that the IOP value in nestlings and juveniles is lower than adults, thus age affects the IOP value. In our study, we did not define the age of the animals. It was thought that differences between Reuter et al., (2011) and our data regarding the same species might be due to uneven age distribution of the raptors.

Stiles et al., (1994) measured the IOP of 3 different raptor species with Tonopen. They measured the IOP 20.6 ± 3.4 mmHg in Red tailed hawks, 20.8 ± 2.3 mmHg in Swainson's hawks and 21.75 ± 3 mmHg in Bald eagles. In our study, the IOP values of than Long-legged buzzards and Golden eagles were measured 26.24 ± 0.47 mmHg and 29.66 ± 1.95 mmHg, respectively. The reason of obtained difference in the same family (Accipitridae) with Stiles et al.'s study may be attributed to different measuring techniques.

To the authors' knowledge, the IOP values measured using rebound tonometer have not previously been reported in *Gyps fulvus*, *Buteo rufinus* and *Aquila chrysaetos* species. Backwith-Cohen et al., (2015) measured IOP 13.3 ± 4 mmHg in *Buteo rufinus* with Tonopen. In another study, Stiles et al., (1994) measured IOP 21.5 ± 3 mmHg in *Aquila chrysaetos* with Tonopen. In a recent study, Hwang et al., (2020) measured IOP 32.8 ± 6.9 mmHg in another species of Vultures (*Aegyptius monachus*) with Tonovet and 20.7 ± 4.5 mmHg with Tonopen. In our study, we measured IOP 29.66 ± 1.95 mmHg in Griffon vultures, 26.24 ± 0.47 mmHg in *Buteo rufinus* and 29.66 ± 1.95 mmHg in *Aquila chrysaetos* with Tonovet. However, the number of the Griffon vultures and Golden eagle species (Griffon vulture: 2, Golden eagle: 6) included in the study is low, more data are needed to reveal reference values in these species.

IOP results could be variable using different measuring devices and physiologic factors such as age, diurnal/nocturnal variation and other conditions (Kimet al., 2017; Reuter et al., 2011; Backwith-Cohen et al., 2015). Moreover, the anatomic structure differences of eyes such as corneal curvature and thickness effect IOP values (Cheng et al., 2006; Murase et al., 2009; Tonnu et al., 2005). The model of the device, the experience of the researcher, the species of animals and transport stress could alter the intraocular pressure values in animals (Broadwater et al., 2007). In mice, cats, and horses, increase in IOP was achieved when the animal's head was positioned under its heart level (Aihara et al., 2003; Kindler et al., 2009; Komaromy et al., 2006). Reuter et al., (2011) reported that body

position has a significant effect on Tawny owls and Common buzzards' IOP values. In addition, pressure applied to the eye or neck during measurement and changes in blood pressure due body positions can be counted among the factors that affect IOP values (Pauli et al., 2006). The risk factors were minimized for the correct measurement in this study. The IOP measurements were performed in dorsal recumbency position in all species. In addition, no pressure was applied to the eyes and neck during the measurements. All measurements were carried out in the same time zones (9am-12pm) by the same researcher and the examination was carried out 10 minutes after the transport process in order to eliminate the stress caused during the transportation of the animals.

CONCLUSION

As a result of this study, there were seven raptors species evaluated in regard to IOP. Complications and problems did not occur during the measurement of IOP. We saw that using TonoVet to measure IOP is very easy in the eye examination of raptors. Rebound

tonometry is a reliable method for measuring IOP in smaller eyes and minimizes stress, well tolerated by raptors. Measurements can be taken without topical anesthesia and results are given within seconds. While there was a positive correlation detected between body weight and IOP values among the species, no correlation was observed between body weight and IOP values within the same species. The IOP values obtained in this study will help veterinary ophthalmologists and wild animal veterinarians to evaluate changes IOP in raptor and contribute to the literature.

The absent of the determination the age and sex of the raptor species are limitations in this study. At the same time the low number of some species (Peregrine falcon, Griffon vulture) could affect the reference values of the IOP. Because of these more studies are needed to determine IOP reference values and factors affecting IOP of the raptor species.

CONFLICT OF INTEREST

None declared by the authors.

REFERENCES

- Aihara, M, Lindsey JD, Weinreb, RN (2003) Episcleral venous pressure of mouse eye and effect of body position. *Curr Eye Res* 27 (6):355-362.
- Barsotti, G, Briganti, A, Spratte, JR, Ceccherelli, R, Breggi, G (2013) Schirmer tear test type I readings and intraocular pressure values assessed by applanation tonometry (XL Tonopent) in normal eyes of four European species of birds of prey. *Vet Ophthalmol* 16 (5):365-369.
- Beckwith-Cohen, B, Horowitz, I, Bdolah-Abram, T, Lublin, A, Ofri, R (2015) Differences in ocular parameters between diurnal and nocturnal raptors. *Vet Ophthalmol* 18 (1), 98-105.
- Broadwater, JJ, Schorling, JJ, Herring, IP, Pickett, JP (2007) Ophthalmic examination findings in adult pygmy goats (*Capra hircus*). *Vet Ophthalmol* 10 (5):269-273.
- Cheng, AC, Fan, D, Tang, E, Lam, DS (2006) Effect of corneal curvature and corneal thickness on the assessment of intraocular pressure using noncontact tonometry in patients after myopic LASIK surgery. *Cornea* 25 (1):26-28.
- Davidson, M (1997) Ocular consequences of trauma in raptors. *Seminars in Avian and Exotic Pet Medicine* 6 (3):121-130.
- Dubicanac, M, Joly, M, Strüve, J, Nolte, I, Mestre-Francés, N, Verdier, JM, Zimmermann, E (2018) Intraocular pressure in the smallest primate aging model: the gray mouse lemur. *Vet Ophthalmol* 21 (3):319-327.
- Holt, DW, Layne, EA (2008) Eye injuries in long-eared owls (*Asio otus*): prevalence and survival. *J Raptor Res* 42:243-247.
- Hwang, J, Kang, S, Seok, S, Ahmed, S, Yeon, S (2020) Ophthalmic findings in cinereous vultures (*Aegypius monachus*). *Vet Ophthalmol* 23 (2):314-324.
- Karimi, V, Asadi, F, Rajaei, SM, Golabdar, S (2020) Intraocular Pressure Measurements Using Rebound Tonometry in Eight Different Species of Companion Birds. *J Avian Med Surg* 34 (4):338-342.
- Kim, J, Kim, D, Kim, EJ, Lee, HB, Kim, NS, Kim, MS (2017) Ophthalmic examination in common kestrels (*Falco tinnunculus*) from South Korea. *J Zoo Wildl Med* 48 (3):683-687.
- Kindler, S, Schieszler, A (2009) The influence of head and body position on the intraocular pressure of the feline eye. *Vet Ophthalmol* 12 (1):66.
- Komaromy, AM, Garg, CD, Ying, GS, Liu, C (2006) Effect of head position on intraocular pressure in horses. *Am J Vet Res* 67 (7):1232-1235.
- Kuhn, SE, Jones, MP, Hendrix, DVH, Ward, DA, Baine, KH (2013) Normal ocular parameters and characterization of ophthalmic lesions in a group of captive bald eagles (*Haliaeetus leucocephalus*). *J Avian Med Surg* 27 (2):90-98.
- Labelle, AL, Whittington, JK, Breaux, CB, Labelle, P, Mitchell, MA, Zarfoss, MK, Schmidt, SA, Hamor, RE (2012) Clinical utility of a complete diagnostic protocol for the ocular evaluation of free-living raptors. *Vet Ophthalmol* 15 (1):5-17.
- Moore, BA, Teixeira, LBC, Sponset, WE, Dubielzig, RR (2017) The consequences of avian ocular trauma: histopathological evidence and implications of acute and chronic disease. *Vet Ophthalmol* 20 (6):496-504.
- Murase, H, Sawada, A, Mochizuki, K, Yamamoto, E (2009) Effects of corneal thickness on intraocular pressure measured with three different tonometers. *Jpn J Ophthalmol* 53 (1):1-6.
- Pauli, AM, Bentley, E, Diehl, KA, Miller, PE (2006) Effects of the application of neck pressure by a collar or harness on intraocular pressure in dogs. *J Am Anim Hosp Assoc* 42 (3):207-211.
- Ress, S, Guyer, C (2004) A retrospective study of mortality and rehabilitation of raptors in the southeastern United States. *J Raptor Res* 38:77-81.
- Reuter, A, Muller, K, Arndt, G, Eule, JC (2011) Reference intervals for intraocular pressure measured by rebound tonometry in ten raptor species and factors affecting the intraocular pressure. *J Avian Med Surg* 25 (3):165-172.
- Reuter, A, Muller, K, Arndt, G, Eule, JC (2010) Accuracy and reproducibility of the TonoVet rebound tonometer in birds of prey. *Vet Ophthalmol* 13 (Suppl 80-5):80-85.
- Seruca, C, Molina-Lopez, R, Pena, T, Leiva, M (2012) Ocular consequences of blunt trauma in two species of nocturnal raptors (*Athene noctua* and *Otus scops*). *Vet Ophthalmol* 15 (4):236-244.
- Stiles, J, Buyukmihci, NC, Farver, TB (1994) Tonometry of normal eyes in raptors. *Am J Vet Res* 55 (4):477-479.
- Tonnu, PA, Ho, T, Newson, T, El Sheikh, A, Sharma, K, White, E, Bunce, C, Garway-Heath, D (2005) The influence of central corneal thickness and age on intraocular pressure measured by pneumotonometer, non-contact tonometry, the Tono-Pen XL, and Goldmann applanation tonometry. *Br J Ophthalmol* 89 (7):851-854.