

# Evaluation of the efficacy of several sclerosing agents for pleurodesis in rats

Cenk BALTA<sup>1</sup>, Mustafa KUZUCUOGLU<sup>2</sup>, Figen ASLAN<sup>3</sup>, Ali Cem YEKDES<sup>4</sup>

<sup>1</sup>Department of Thoracic Surgery, Hatay Mustafa Kemal University Health Application and Research Hospital, Hatay, Turkey

<sup>2</sup>Department of Thoracic Surgery, İzmir Katip Çelebi University Health Application and Research Hospital, İzmir, Turkey

<sup>3</sup>Department of Pathology, Kutahya Health Sciences University Health Application and Research Hospital, Kutahya, Turkey.

<sup>4</sup>Department of Internal Medicine, Balıkesir University Health Application and Research Hospital, Balıkesir, Turkey

**Corresponding Author:** Cenk BALTA

**E-mail:** [drcenkbalta@gmail.com](mailto:drcenkbalta@gmail.com)

**Submitted:** 23.02.2022

**Accepted:** 30.05.2022

## ABSTRACT

**Objective:** This study aims to evaluate the efficiencies and effects of different sclerosing agents.

**Materials and Methods:** Thirty-five female Wistar-albino rats were included in this study and divided into five groups randomly. Isotonic saline (group 1), iodopovidone (group 2), rifamycin (group 3), autologous blood (group 4), talc (group 5) were given into intrapleural space. On postoperative 28th day, ipsilateral and contralateral pleural and parenchymal fibrosis and inflammation were evaluated.

**Results:** There were statistically differences between control and other groups on macroscopically pleural fibrosis examination ( $p=0.004$ ,  $p=0.001$ ,  $p=0.001$ ,  $p=0.000$ , respectively). Microscopically pleural fibrosis were determined in all groups when compared to control group ( $p=0.023$ ,  $p=0.023$ ,  $p=0.035$ ,  $p=0.001$ , respectively). There were no significant differences between sclerosing agent groups ( $p>0.05$ ). Significant differences were observed according to microscopic pleural inflammation evaluation between talc group and other groups. There was superiority in talc group according to intraparenchymal inflammation grade compared to other groups ( $p=0.010$ ,  $p=0.042$ ,  $p=0.030$ , respectively). Macroscopically, fibrosis and microscopically, inflammation were significantly observed between talc and other groups in the contralateral pleura ( $p = 0.037$  and  $p=0.009$ , respectively).

**Conclusion:** Iodopovidone, autologous blood, talc, and rifamycin can be used as effective pleurodesis agents. However, we found that rifamycin and autologous blood are safer as effective pleurodesis agents. We think that these two agents can be used in patients with secondary lung diseases due to their less intraparenchymal inflammation rates. It may be advantageous to prefer other sclerosing agents which has lower costs and less side effects comparing to talc.

**Keywords:** Pleurodesis, Pleural effusions, Pleural inflammation, Animal experiments

## 1. INTRODUCTION

Pleurodesis is a medical procedure to induce an inflammatory reaction between the visceral and parietal pleura to obtain adhesion of pleural layers. Chemical and mechanical pleurodesis are the two methods used for inducing pleurodesis. Chemical pleurodesis is mainly used for avoiding recurrences of effusions in patients with malignant pleural effusion. Sclerosing agents administered under videothoracoscopy (VATS) or through a thoracic catheter act on the mesothelial layer, leading to inflammation. The resulting fibrotic process induces adhesion between the visceral and parietal pleura [1].

Despite the use of several agents including tetracycline, bleomycin, talc powder, silver nitrate, iodopovidone, and autologous blood samples for this purpose; the debate for identifying the treatment

of choice agent still continues [2]. An effective, available, low-cost, easy to administer, high molecular weight, and sterilizable agent with a low potential for side effects should be preferred in the treatment [3]. Tetracycline was the most commonly used agent for pleurodesis in the 1980s; however, its popularity has declined due to problems with its production and the risk of hemithorax. The efficacy of bleomycin is lower compared to other agents but it is an expensive agent. It is reported that the use of silver nitrate causes severe pain and hemothorax [3]. Today, the most commonly used agent for pleurodesis is talc powder. It has been demonstrated that talc powder administration is associated with the emergence of acute respiratory distress syndrome (ARDS) resulting from the penetration of small particles into alveoli [4].

**How to cite this article:** Balta C, Kuzucuoglu M, Aslan F, Yekdes AC. Evaluation of the efficacy of several sclerosing agents for pleurodesis in rats. *Marmara Med J* 2022;35(3): 297-302. doi: 10.5472/marumj.1191101

In this study, we aimed to determine the efficacy of the sclerosing pleurodesis agents used in our clinical practice and to identify the most efficacious one by using comparative analyses.

## 2. MATERIALS and METHODS

The study was designed as a randomized and prospective trial. Because of rats' high tolerance to surgical procedures, low costs, and easy reproducibility, growth, and care characteristics; these animals were selected as the experimental animals to be used in our study. This study was conducted in the experimental animal laboratory of Balikesir University following the approval obtained from the Animal Experiments Local Ethics Committee of Balikesir University (Decision No: 2019/10-2).

### Aim and the Study Design

In the study, 35 female albino Wistar rats of 250-300 grams body weight on the average were used. The rats were randomized into five groups.

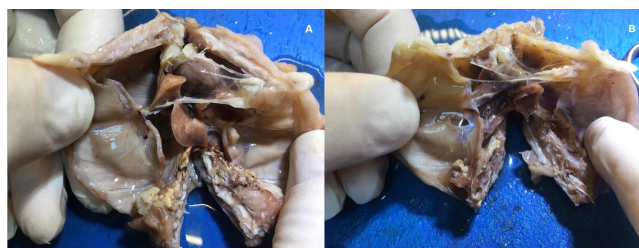- Group 1 was assigned as the control group and the rats in Group 1 were administered 1cc of 0.9% saline solution.
- The rats in Group 2 received 1 cc of 2% iodopovidone.
- The rats in Group 3 received 12.5 mg/kg rifamycin (RIF ampoules – Koçak Farma, Istanbul, Turkey) in a volume of 1cc.
- Autologous blood samples of 0.5 cc collected from the tail veins of the rats were administered to the rats in Group 4 at a dose of 2 ml/kg.
- Group 5 received 50 mg/kg sterile talc (NovatechSA – Steritalc®, Marseille, France) at a volume of 1 cc.

### Surgical Technique

Ketamine hydrochloride (Alfamine vial, Ege-vet Pharmaceutical Co. Izmir, Turkey) and xylazine hydrochloride (Alfazyme vial, Ege-vet Pharmaceutical Co. Izmir, Turkey) were intramuscularly administered to the rats at doses of 100 mg/kg and 10 mg/kg, respectively, to obtain general anesthesia. After applying general anesthesia to the rats, they were brought to the right lateral decubitus position. The thoracic areas of the rats on the right side were shaved and cleaned. Asepsis was obtained by cleaning the site of surgery with iodopovidone. Access to the thoracic cavity was obtained through a 5 mm-incision made in the intercostal area in the midline of the left lateral hemithorax. The sclerosing agents were administered into the intrapleural space through a 24G venous catheter at the doses specified above. The rats were taken into the palm and they were turned around to make several circles in the air so that the active agent would be spread throughout the thoracic cavity. Then, the free air between the pleural layers was aspirated with an injector and catheter to avoid a potential pneumothorax. The incision was closed with 3/0 polypropylene sutures. Ventilator support was not applied during surgical intervention. Paracetamol was administered intraperitoneally at a dose of 10 mg/kg to all rats in the experiment before they woke up. The rats were followed up at separate cages in the postoperative period. A total of four

rats died; 2 in the isotonic saline solution group and 2 in the blood group, during the surgical interventions and in the 24-hour period after surgery.

The rats were kept alive for 4 weeks under appropriate living conditions with optimum temperature and humidity and 12-hour light and 12-hour dark cycles. They were provided with access to water and they were fed with pellet feed. No movement disorders, feeding disorders, or any other pathologies were observed in the rats after the surgical procedures. All of the rats were sacrificed with cervical dislocation under general anesthesia obtained by the administration of 100 mg/kg ketamine hydrochloride and 10 mg/kg xylazine hydrochloride to each rat at the end of the fourth week. En-bloc resection of the whole thoracic wall was performed, dissecting the muscle and connective tissue (Figure 1). After the specimens were washed with saline solution, they were placed in 10% formaldehyde solution.

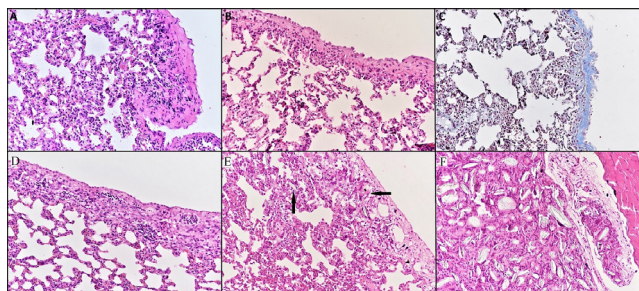


**Figure 1.** En bloc resection of the whole thoracic wall A) adhesions in ipsilateral hemithorax (rifamycin received group) B) adhesions in both hemithoraces (talc received group)

### Pathological Examination

Both pleural cavities in each rat of all groups were exposed as described previously [3,5]. Firstly, both pleural cavities in each rat were exposed by incising all of the ribs bilaterally in both hemithoraces approximately along the midline and the diaphragm. Then, the medial parts of the anterior ribs and the sternum were excised so that the lungs and the pleural cavities could be observed appropriately.

The macroscopic degree of pleurodesis was determined in the groups in a blinded fashion as specified below [3,5] (Figure 2).



**Figure 2.** (A) Microscopic section of Grade 3 visceral pleural inflammation and Grade 3 lung inflammation in the iodopovidone group (H-E x 200). (B) Microscopic section of Grade 2 visceral pleural inflammation and Grade 2 lung inflammation in the rifamycin group (H-E x 200). (C) Microscopic section of Grade 3 visceral pleural thickening in the rifamycin

group (trichrome staining, x 200). (D) Microscopic section of Grade 3 visceral pleural inflammation and Grade 2 lung inflammation in the Blood group (H-E x 200). (E) Microscopic section of Grade 4 visceral pleural inflammation and Grade 3 lung inflammation in the Talc group. Granulomatous reaction rich in foreign body giant cells developing against talc crystals in the visceral pleura and lung parenchyma (arrow) (H-E x 200). (F) Microscopic section of Grade 4 parietal pleural inflammation in the Talc group. Granulomatous reaction rich in foreign body giant cells developing against talc crystals in the parietal pleura (H-E x 200).

- 0: The pleural cavities and the lungs looked normal.
- 1: No adhesions were observed; however, inflammation was observed in the pleural cavity, looking ragged with fibrin accumulation.
- 2: Presence of a few scattered adhesions
- 3: Presence of generally scattered adhesions
- 4: Complete adhesion resulting in the loss of the pleural space

Samples of parietal pleura, visceral pleura, and lung tissue were collected from both hemithoraces; from the areas, which represented macroscopic pleurodesis best. The samples were fixed in 10% formalin and underwent routine tissue procedures. Sections of 4  $\mu$ m thickness were obtained and stained with hematoxylin-eosin. Furthermore, Masson's trichrome staining was performed to evaluate fibrosis better. The prepared tissue sections were examined under a light microscope to evaluate inflammation and fibrosis.

**Table I.** Mean values of sclerosing agents

Groups	n	Macroscopically pleural fibrosis	Microscopically pleural fibrosis	Microscopically pleural inflammation	Intraparenchymal inflammation
		Mean $\pm$ STD	Mean $\pm$ STD	Mean $\pm$ STD	Mean $\pm$ STD
Saline	5	0.80 $\pm$ 0.447	1.00 $\pm$ 1.000	1.00 $\pm$ 1.000	1.20 $\pm$ 0.447
Iodopovidone	7	2.43 $\pm$ 0.787	2.57 $\pm$ 0.976	2.43 $\pm$ 0.787	2.00 $\pm$ 0.816
Rifamycin	7	2.71 $\pm$ 0.488	2.57 $\pm$ 0.535	2.43 $\pm$ 0.535	1.57 $\pm$ 0.535
Autologous Blood	5	2.80 $\pm$ 1.095	2.60 $\pm$ 0.894	2.20 $\pm$ 0.837	1.40 $\pm$ 0.894
Talc	7	3.00 $\pm$ 0.577	3.14 $\pm$ 0.690	3.71 $\pm$ 0.756	2.71 $\pm$ 0.756

n: number, STD: standard derivation

**Table II.** Comparison of sclerosing agents in ipsilateral hemithorax

Macroscopically pleural fibrosis					Microscopically pleural fibrosis				
	Talc	Autologous Blood	Rifamycin	Iodopovidone		Talc	Autologous Blood	Rifamycin	Iodopovidone
Saline	0.000	0.001	0.001	0.004	Saline	0.001	0.035	0.023	0.023
Iodopovidone	0.555	0.892	0.939		Iodopovidone	0.691	1	1	
Rifamycin	0.939	1			Rifamycin	0.691	1		
Autologous Blood	0.988				Autologous Blood	0.789			
Microscopically pleural inflammation					Intraparenchymal inflammation				
	Talc	Autologous Blood	Rifamycin	Iodopovidone		Talc	Autologous Blood	Rifamycin	Iodopovidone
Saline	0.000	0.135	0.031	0.031	Saline	0.010	0.991	0.897	0.331
Iodopovidone	0.034	0.986	1		Iodopovidone	0.353	0.608	0.791	
Rifamycin	0.034	0.986			Rifamycin	0.042	0.994		
Autologous Blood	0.020				Autologous Blood	0.030			

During these examinations, the investigator was blinded to the descriptive characteristics of the groups.

Degrees of microscopic inflammation and fibrosis [3,5]:

- 0: Not available
- 1: Insignificant/suspected
- 2: Mild
- 3: Moderate
- 4: Severe

### Statistical Analysis

Sample size for the animal studies are suggested as minimum 5-7 animals per group [6]. All parameters were presented as mean  $\pm$  standard deviation. The intergroup relationships of the parameters were evaluated with the one-way ANOVA test. Then, the Tukey test was performed for post hoc analysis to determine differences between the subgroups. In all statistical analyzes, p-values of less than 0.05 were considered significant.

### 3. RESULTS

The scores of macroscopic pleural fibrosis, microscopic pleural fibrosis, microscopic pleural inflammation, and intraparenchymal inflammation were presented in Table I as mean  $\pm$  standard deviation.

**Table III.** Mean values and comparison of sclerosing agents in contralateral hemithorax

Groups	n	Macroscopically pleural fibrosis Mean±STD	Microscopically pleural fibrosis Mean±STD	Microscopically pleural inflammation Mean±STD	Intraparenchymal inflammation Mean±STD
Saline	5	0.40±0.548	0.40±0.548	0.40±0.548	1.00±0.707
iodopovidone	7	1.00±0.577	1.29±1.113	1.29±0.756	1.86±0.900
Rifamycin	7	1.14±0.378	1.14±0.378	1.29±0.488	1.86±0.690
Autologous Blood	5	0.80±0.837	1.00±0.707	1.00±0.00	0.80±0.1.095
Talc	7	1.43±0.535	1.14±0.690	1.57±0.535	1.57±0.787
ANOVA test (p) between groups		0.059	0.016	0.339	0.129

n: number, STD: Standard derivation

### Evaluation of the ipsilateral (left) hemithorax

It was observed that all sclerosing agents caused more pleural fibrosis macroscopically compared to the control group (iodopovidone:  $p=0.004$ , rifamycin:  $p=0.001$ , autologous blood:  $p=0.001$ , talc:  $p=0.000$ ). However, no statistically significant differences were observed between the groups receiving sclerosing agents (Table II).

While all sclerosing agents caused statistically more pleural fibrosis microscopically compared to the control group (iodopovidone:  $p=0.023$ , rifamycin:  $p=0.023$ , autologous blood:  $p=0.035$ , talc:  $p=0.001$ ), no superiority of a sclerosing agent over the other was observed (Table II).

In the group of rats; which received talc, microscopic pleural inflammation occurred to a statistically significantly higher degree compared to the other groups. Microscopic inflammation in the pleura was observed more in the rifamycin and iodopovidone groups when compared to the control group ( $p=0.031$ ,  $p=0.031$ , respectively). It was observed that autologous blood administration caused less inflammation in the pleura microscopically compared to the other sclerosing agents used for pleurodesis in the other groups (Table II).

Intraparenchymal inflammation developed statistically significantly more in the talc pleurodesis group compared to the control group ( $p=0.010$ ), rifamycin group ( $p=0.042$ ), and the autologous blood group ( $p=0.030$ ). While the intraparenchymal inflammation was not statistically significantly different between the talc pleurodesis and iodopovidone groups ( $p=0.353$ ), the intraparenchymal inflammation in the iodopovidone pleurodesis group was not statistically significant when compared to the control group ( $p=0.331$ ) (Table III).

### Evaluation of the contralateral (right) hemithorax

The examination of the macroscopic pleural fibrosis scores revealed that the macroscopic pleural fibrosis was statistically significant in the contralateral pleura of the group of rats; which were administered talc ( $p=0.037$ ). However, no statistically significant contralateral pleural fibrosis was observed in the other groups (Table III).

Microscopic pleural inflammation was significant in the talc pleurodesis group compared to the control group ( $p=0.009$ ); however, no significant pleural inflammation was observed in

the other groups compared to the control group. There were no statistically significant differences in the microscopic pleural fibrosis and intraparenchymal inflammation scores among the groups in the experiment.

## 4. DISCUSSION

Pleurodesis can be used for the treatment of recurrent malignant effusions and prolonged air leakage. Effective induction of pleural inflammation and fibrosis is recommended for pleurodesis; however, the absolute superiority of sclerosing agents over each other has not been demonstrated yet [7]. This study compared the efficacy of three commonly used sclerosing agents in clinical practice; including talc, autologous blood, and iodopovidone, and a rarely used agent, rifamycin, for pleurodesis and compared the resulting degree of parenchymal inflammation induced by these agents.

Autologous blood was used by Robinson for the first time in 1987 with a success rate of 85% for the treatment of persistent air leakage [8]. Özpolat et al., conducted a study and reported that autologous blood pleurodesis was inexpensive, easy to administer, and an effective method [2]. They reported that the administration of 2-3 mL/kg, but not 1 mL/kg autologous blood, effectively resulted in macroscopic and microscopic pleurodesis. Lang-Lazdunski et al., did not advise the use of more than 50 mL of autologous blood for pleurodesis as that volume might cause empyema [9]. In our study, we administered autologous blood at a dose of 2 mL/kg. We determined that the administration of autologous blood resulted in statistically significant pleural fibrosis both macroscopically and microscopically when compared to the control group; however, the resulting microscopic pleural inflammation was not statistically significantly different. The failure to induce pleural inflammation with autologous blood in our experiment supported the Droghetti et al., study [10]; suggesting that autologous blood pleurodesis is a less painful procedure compared to other methods. Furthermore, we determined that the degree of intraparenchymal inflammation was not statistically significantly different compared to the control group; which was administered physiological saline solution only. These results showed that pleurodesis with the use of 2 mL/kg autologous blood induced effective pleural fibrosis and did not cause inflammation in the pleura and the lung parenchyma.

Talc pleurodesis was first performed by Bethune in a patient; who developed pulmonary collapse associated with tuberculosis surgery [11]. In an experimental animal study; which evaluated

the efficacy of talc pleurodesis, Light et al., found that microscopic and macroscopic inflammation and fibrosis increased significantly with increasing doses [5]. Moreover; the authors reported that the risk of respiratory insufficiency, acute pneumonia, and adult respiratory distress syndrome (ARDS) increased with the increasing talc doses. Rehse et al., [12] reported that respiratory complications and ARDS developed in 33% and 9% patients, respectively, in association with talc pleurodesis in their study on 5 patients [12]. Yildirim et al., reported that side effects such as fever, chest pain, vomiting, arrhythmia, hypotension, and convulsion were observed in their talc pleurodesis study with an 81.6% success rate [13]. Werebe et al., found talc particles in the coronary arteries, meninges, urinary tracts, pulmonary arteries, and myocardial tissue of rats 24 hours after the intrapleural talc administration regardless of the dose [14]. Yalçınkaya et al., found that non-steroidal anti-inflammatory drugs (NSAIDs) used in the symptomatic treatment of pleurodesis-associated pain reduced the efficacy of pleurodesis-inducing procedures [15]. We administered talc at a dose of 50 mg/kg to the rats in our study. We found out that the administration of talc was statistically superior in inducing macroscopic and microscopic pleural fibrosis compared to the control group; however, these results in the talc pleurodesis group were not statistically different compared to the iodopovidone, rifamycin, and autologous blood groups. The evaluation of the pleural inflammation under the microscope revealed the significant statistical superiority of talc over the saline solution and the other agents used in the study. Furthermore, we found out that talc induced more intraparenchymal inflammation compared to the control group and the rifamycin and autologous blood groups. Similarly, Yazıcıoğlu et al., found significantly more intraparenchymal inflammation in the talc group compared to the control group [16]. The evaluation of the contralateral hemithorax revealed that the rates of the macroscopic pleural fibrosis and microscopic pleural inflammation were significantly different in the talc group again compared to the other groups. In their study with talc pleurodesis; Gözübüyük et al., found statistically significantly higher incidences of acute and subacute oedema and haemorrhage in the contralateral lung, suggesting that these could be the causing factors resulting in ARDS, which was reported as a talc-associated complication [17].

Rifamycin was observed to cause fibrosis and inflammation during wound healing. Döngel et al., found out that 20 mg/kg rifamycin induced pleurodesis microscopically and macroscopically as much effective as talc and that the efficacy of rifamycin was statistically higher compared to autologous blood pleurodesis [18]. Furthermore, the authors stressed that rifamycin should be considered as an alternative to talc because it was less costly compared to talc and did not cause side effects statistically significantly. In our study, we administered 12.5 mg/kg rifamycin to the rats for pleurodesis. We found out that rifamycin caused macroscopic and microscopic pleural fibrosis significantly compared to the control group; however, these results were not statistically significantly different compared to the talc and autologous blood groups. We observed that talc induced more microscopic pleural inflammation compared to rifamycin. However, rifamycin caused less inflammation in the lung parenchyma compared to talc. Although,

we did not observe any statistical differences in rifamycin-induced intraparenchymal inflammation compared to the two other sclerosing agents, iodopovidone and autologous blood; the mean scores of intraparenchymal inflammation were observationally less with rifamycin (mean=1.57±0.535) compared to iodopovidone (mean=2.00±0.816).

Iodopovidone is a topical antiseptic. It was used for pleurodesis in 1991 for the first time [19]. Agarwal et al., reported that iodopovidone was a safe and 90.6% effective agent for pleurodesis, causing fewer side effects compared to talc [20]. In a study comparing the efficacy of iodopovidone and bleomycin pleurodesis, no significant differences were found in the efficacy and associated side effects between those two sclerosing agents [21]. Although, the mechanism of iodopovidone pleurodesis is not fully known, it is suggested that it makes the environment acidic, resulting in an inflammatory response [20]. The study by Ibrahim et al., compared the efficacy and side effects of iodopovidone and talc but found no statistically significant differences between them [22]. Although, it has been suggested that the iodopovidone use may impair thyroid functions [23], Yeğinsu et al., did not detect any effects of 2% iodopovidone on thyroid functions in their study of pleurodesis [24]. In our study, we administered 2% iodopovidone to the rats in Group 2. It was observed that iodopovidone produced more pleural fibrosis macroscopically and microscopically compared to the control group. However, no significant differences of iodopovidone effects were observed compared to the other sclerosing agents used in the experiment. We found out that the administration of iodopovidone resulted in statistically significantly more microscopic pleural fibrosis compared to the control group but this effect was statistically insignificant compared to the rifamycin and autologous blood groups. We observed that talc induced more microscopic pleural inflammation compared to iodopovidone. The examination of intraparenchymal inflammation revealed no significant differences of iodopovidone compared to the other sclerosing agents used in the experiment.

## 5. CONCLUSION

In conclusion; iodopovidone, autologous blood, talc, and rifamycin can be used as effective pleurodesis agents. However, our findings demonstrate that rifamycin and autologous blood are safer agents for the treatment of patients with the diseases of pulmonary parenchyma compared to the other sclerosing agents used in this experiment because rifamycin and autologous blood induce intraparenchymal inflammation to a lesser degree. The sclerosing agents used in our study are less costly compared to talc. Therefore, the selection of these agents for pleurodesis may offer further advantages. Studies about the cost-effectiveness of these agents are warranted to obtain further information.

## Compliance with Ethical Standards

**Ethical Approval:** The present study protocol was approved by the approval obtained from the Animal Experiments Local Ethics Committee of Balıkesir University (Decision No: 2019/10-2).

**Financial Support:** This manuscript did not receive any specific grant from funding agencies in the public, commercial, or not-for-profit sectors.

**Conflict of Interest:** The authors have stated explicitly that there are no conflicts of interest in connection with this article.

**Authors' Contribution:** CB: Conception and design of the work, and the acquisition, analysis, and interpretation of the data for the work and agreement to be accountable for all aspects of the work in ensuring that questions related to the accuracy or integrity of any part of the work were appropriately investigated and resolved; final approval of the version to be published; drafting the work; designing of the work; Interpretation of data for the work.

MK: Drafting the work or revising it critically for important intellectual content; Designing of the work; interpretation of data for the work.

FA: Substantial contributions to the conception or design of the work, or the acquisition, analysis, or interpretation of data for the work, drafting the work or revising it critically for important intellectual content.

ACY: The acquisition, analysis, or interpretation of data for the work, drafting the work or revising it critically for important intellectual content. All authors approved the final version of the article.

## REFERENCES

- [1] Light RW, Vargas FS. Pleural sclerosis for the treatment of pneumothorax and pleural effusion. *Lung* 1997;175:213-23.
- [2] Ozpolat B, Gazyagci S, Gözübüyük A, Ayva S, Atinkaya C. Autologous blood pleurodesis in rats to elucidate the amounts of blood required for reliable and reproducible results. *J Surg Res* 2010;15;161:228-32. doi: 10.1016/j.jss.2009.01.027.
- [3] Teixeira LR, Vargas FS, Acencio MM, Bumlai RU, Antonangelo L, Marchi E. Experimental pleurodesis induced by antibiotics (macrolides or quinolones). *Clinics* 2006;61:559-64.
- [4] Ahn HY, Cho JS, Kim YD, et al. Efficacy of mistletoe for chemical pleurodesis in rats without malignancy. *Open Med (Wars)* 2015;4;10:346-51. doi: 10.1515/med-2015-0051.
- [5] Light RW, Wang NS, Sassoon CS, Gruer SE, Vargas FS. Talc slurry is an effective pleural sclerosant in rabbits. *Chest* 1995;107:1702-6.
- [6] Arifin WN, Zahiruddin WM. Sample size calculation in animal studies using resource equation approach. *Malays J Med Sci* 2017; 24: 101-5. doi: 10.21315/mjms2017.24.5.11.
- [7] Mitchem RE, Herndon BL, Fiorella RM, Molteni A, Battie CN, Reisz GR. Pleurodesis by autologous blood, doxycycline, and talc in a rabbit model. *Ann Thorac Surg* 1999;67:917-21.
- [8] Robinson CLN. Autologous blood for pleurodesis in recurrent and chronic spontaneous pneumothorax. *Can J Surg* 1987;30:428-9.
- [9] Lang-Lazdunski L, Coonar AS. A prospective study of autologous 'blood patch' pleurodesis for persistent air leak after pulmonary resection. *Eur J Cardiothorac Surg* 2004;26:897-900.
- [10] Droghetti A, Schiavini A, Muriana P, et al. Autologous blood patch in persistent air leaks after pulmonary resection. *J Thorac Cardiovasc Surg* 2006;132:556-9.
- [11] Bethune N. Pleural poufrage: new technique for deliberate production of pleural adhesions as preliminary to lobectomy. *J Thorac Surg* 1935; 4:251-61.
- [12] Rehse DH, Aye RW, Florence MG. Respiratory failure following talc pleurodesis. *Am J Surg* 1999;177:4:437-40.
- [13] Yildirim H, Metintas M, Ucgun I, Erginel S, Alatas F, Kurt E. Talc Plörodezeze bağı gelişen yan etkiler. *Osman Gazi Tıp Dergisi* 2005;27:51-6.
- [14] Werebe EC, Pazetti R, Milanez de Campos JR, et al. Systemic distribution of talc after intrapleural administration in rats. *Chest* 1999;115:190-3.
- [15] Yağcınkaya S, Yağcınkaya U. Non-steroid anti-inflammatory drugs reduce the efficacy of autologous blood pleurodesis. *Turk Gogus Kalp Dama* 2019;27:343-9. doi: 10.5606/tgkdc.dergisi.2019.17544
- [16] Yazıcıoğlu A, Uysal S, Sahinoğlu T, Subasi M, Demirag F, Yekeler E. Does sericin, as a novel pleurodesis agent, have higher effectiveness compared to talcum powder, doxycycline, and silver nitrate pleurodesis? *Arch Bronconeumol* 2019;55:357-67. doi: 10.1016/j.arbres.2018.10.003.
- [17] Gözübüyük A, Ozpolat B, Çiçek AF, et al. Comparison of side effects of oxytetracycline and talc pleurodesis: an experimental study. *J Cardiothorac Surg* 2010;13;5:128. doi: 10.1186/1749-8090-5-128.
- [18] Dongel İ, Sunam GS, Külahçı Ö, Ceran S. A comparison of the efficacies of heterologous blood, rifamycin, and talc as pleural sclerosants in rabbits: An experimental study. *Turk Gogus Kalp Dama* 2012;20:590-95.
- [19] Echavarría A, Pinzón V, Barés JP, Fernández E. Intracavitary treatment of malignant pleural effusion with iodine-povidone. *Rev Med Panama* 1991;16:69-74.
- [20] Agarwal R, Aggarwal AN, Gupta D, Jindal SK. Efficacy and safety of iodopovidone in chemical pleurodesis: A meta-analysis of observational studies. *Respir Med* 2006;100:2043-7, doi:http://dx.doi.org/10.1016/j.rmed.2006.02.009.
- [21] Bagheri R, Noori M, Rajayi M, et al. The effect of iodopovidone versus bleomycin in chemical pleurodesis. *Asian Cardiovasc Thorac Ann* 2018;26:382-386. doi: 10.1177/021.849.2318778485.
- [22] Ibrahim IM, Dokhan AL, El-Sessy AA and Eltaweel ME. Povidone-iodine pleurodesis versus talc pleurodesis in preventing recurrence of malignant pleural effusion. *J Cardiothorac Surg* 2015;1;10:64. doi: 10.1186/s13019.015.0270-5.
- [23] Bryant WP, Zimmerman D. Iodine-induced hyperthyroidism in a newborn. *Pediatrics*. 1995;95:434-6. Erratum in: *Pediatrics* 1995;96:779.
- [24] Yeginsu A, Karamustafaoglu A, Ozugurlu F, Etikan I. Iodopovidone pleurodesis does not effect thyroid function in normal adults. *Interact Cardiovasc Thorac Surg* 2007;6: 563-4.